

CLINICAL ANALYSIS OF REMAINING CORONAL TOOTH STRUCTURE IN RELATION WITH PREFABRICATED METAL POSTS IN MOLARS- A RETROSPECTIVE ANALYSIS

Keerthana T¹, Sindhu Ramesh², Deepak. S³

Abstract

Introduction

Endodontically treated teeth which have extensive structural defects due to caries, access cavity preparation require post and core management for retention purpose. The clinical decision is to decide whether an endodontically treated tooth requires a post and a crown poses a challenge to dental practitioners.

Aim; *The study aims at analysing remaining coronal tooth structure in relation with prefabricated metal posts in molars.*

Materials and Method: *This retrospective clinical study evaluated the patients who received prefabricated metal posts in endodontically treated molars from the department of Conservative Dentistry and Endodontics in a dental college located at Chennai. Total of 373 patient's records were evaluated from June 2019 to March 2020 and based on inclusion and exclusion criteria, selected data consisted of 219 patients who received prefabricated metal posts in endodontically treated molars. Inclusion criteria consisted of patients aged between 18-60 years who received prefabricated metal posts in endodontically treated molars. Exclusion criteria consisted of patients who received FRC and cast post in endodontically treated teeth other than molars.*

Results; *In this study of 219 patients (104 are females, 115 are males with a mean age group of 30 years) were included. It is observed that there is a significant difference among the groups. Group B (coronal tooth structure- 2 to 4 mm) were highly noted in endodontically treated molars with prefabricated metal posts compared to other groups with p value < 0.05 .*

Conclusion : *The clinical analysis in relation to endodontically treated molars with prefabricated metal posts showed the remaining coronal tooth structure of 2-4 mm was highly noted although it's not statistically significant. 2-4mm of remaining coronal tooth structure is essential for preventing root fracture, post dislodgement and fracture.*

Keywords: *Post and core, root canal treated molars, coronal tooth structure, prefabricated metal posts.*

¹ Department of Conservative Dentistry and Endodontics, Saveetha Dental College and Hospitals, Saveetha Institute of Medical and technical Sciences, Saveetha University, Chennai, India, Mail Id : 151906007.sdc@saveetha.com

² Corresponding Author: Professor, Department of Conservative Dentistry and Endodontics, Saveetha Dental College and Hospitals, Saveetha Institute of Medical and technical Sciences, Saveetha University, Chennai, India, Mail Id : sindhuramesh@saveetha.com

³ Senior Lecturer, Department of Conservative Dentistry and Endodontics Saveetha Dental College and Hospitals, Saveetha Institute of Medical and technical Sciences, Saveetha University, Chennai, India, Mail Id : deepaks.sdc@saveetha.com

INTRODUCTION

A post is a metallic structure placed within root canal treated teeth to retain the core structure. Retention of endodontically treated teeth with post and core unit is highly recommended when the teeth are having less remaining coronal tooth structure[1].

Retention of various post structure to core restorative materials is an important factor in selection of prefabricated post systems and restorative materials for restoring endodontically treated teeth.[2] The post is inserted in the root canal and the core is retained, then it supports final restoration, simulating prepared tooth structure[3].

While custom cast posts and cores are traditionally used to restore endodontically treated teeth, prefabricated post systems have become popular later. Over the years, various prefabricated post systems have been introduced and used in clinical settings[4]. Many methods and techniques for post and core construction are available. The characteristics of each system are determined by post and core design[5–7].

Post structures are either flat, spherical, serrated and the most commonly used core materials are composite, glass ionomer cement, resin based luting cement[8–10]. The advantages of glass ionomer cement as core material includes bonding to tooth structure and fluoride release, remineralization in case of carious lesions[11,12]. Core materials are mechanically adapted to post heads following post cementation to prepare the root canal[13].

The metal posts are more resistant to fracture, but their high elastic modulus in comparison with dentin can induce stresses in radicular dentin. Both prefabricated metal posts and cast posts have shown to be predictable and successful materials[14,15]. The aim of this study was to analyse the remaining coronal tooth structure in relation with prefabricated metal posts in molars.

MATERIALS AND METHODS

Study Design

Single centered retrospective study

Ethical Approval

Approval for the project was obtained from the Institutional Review Board of Saveetha Institute of Medical and Technical Sciences, Chennai, India on Date 18/04/2020 [SRB Reference No. SDC/SIHEC/2020/DIASDATA/0619-0320]. This retrospective clinical study evaluated the patients who received prefabricated metal posts in endodontically treated molars.

Eligibility Criteria

Inclusion Criteria

Patients aged 18- 60 years having endodontically treated molars, treated with prefabricated metal posts.

Exclusion criteria

Patients who received prefabricated posts, FRC posts, cast posts in endodontically treated teeth other than molars.

Data Extraction

This study was based on an evaluation of the data of 373 patient's records from June 2019 to March 2020, that met the inclusion and exclusion criteria. Data collection was accomplished using standardized electronic form

designed to collect information related to subjects' demographic features, remaining coronal tooth structure. The final data was exported to excel and saved on a secure server for analysis. The case selection and data extraction is shown in (Flow chart 1).

Sample Size

The sampling method used was the data evaluated from the records collected. Of total, 373 patients who received prefabricated metal posts, 219 patients were selected for this study based on inclusion and exclusion criteria. After grouping of parameters, data copied to SPSS software. The statistical analysis between different groups was carried out in SPSS software. Chi square test was done to compare the remaining coronal tooth structure to other three parameters – age, gender, teeth number.

The grouping was done as follows:

Groups

Group A: Remaining coronal tooth structure of 1-2mm

Group B : Remaining coronal tooth structure of 2-4mm

Group C : Remaining coronal tooth structure of 4-6mm

Clinical Outcome

The clinical outcome of this study was to compare and analyse the remaining coronal tooth structure in endodontically treated molars which received prefabricated metal posts. All the patients who received prefabricated metal posts in endodontically treated molars were assessed clinically and radiographically to analyse the remaining coronal tooth structure.

Clinical Protocol

The clinical protocol of the patients receiving prefabricated metal posts in molars is to check the status of root canal treatment prior any procedure as it plays a major role in the prognosis of the treatment. After that step, selection of post type is decided based on the following factors such as root length, tooth anatomy, root width, canal configuration, amount of remaining coronal tooth structure. Considering metal posts, several factors such as post length, post diameter, design and luting cement should be decided before removing the gutta percha in the canal.

Study Outcome

As it was a retrospective analysis, over 373 patient's records of prefabricated metal posts in endodontically treated teeth were collected. After applying inclusion and exclusion criteria, 219 patient's records of prefabricated metal post in endodontically treated molars were analysed. In each case, remaining coronal tooth structures were assessed by clinical findings. Comparative analysis showed in maxillary and mandibular molars with prefabricated metal posts, 2-4 mm remaining coronal tooth structure was highly noted.

Statistical Analysis

Chi square test was done to assess these parameters. The outcome data was represented in the form of tables and graphs. The four tables represent the prefabricated metal posts in molars done based on the age, gender, teeth number of the patient. The graphs represent the correlation between these parameters- Correlation of age and remaining coronal tooth structure in endodontically treated molars, gender and remaining coronal tooth structure in endodontically treated molars, teeth number and remaining coronal tooth structure in endodontically treated molars.

After grouping of parameters, data was copied to SPSS software. The statistical analysis between all three groups was carried out in SPSS software. Chi square test was done to compare the remaining coronal tooth structure to other three parameters – age, gender, teeth number.

RESULTS

The clinical database system resulted in a total of 373 patient charts identifying prefabricated posts in endodontically treated molars over a period of one year. After applying inclusion and exclusion criteria, around 219 met with the criteria.

In this study, analysing coronal tooth structure in endodontically treated molars with prefabricated metal posts, group B (remaining coronal tooth structure- 2 to 4 mm) was highly noted than group A (remaining coronal tooth structure- 1 to 2mm), group C(remaining coronal tooth structure-4 to 6mm). In this study consisting of endodontically treated molars, 83 maxillary molars were treated with prefabricated metal posts, 136 mandibular molars were treated with prefabricated metal posts.

In the 18-30 years of age group -33.86% of cases, In the 30-40 years of age group- 18.4% of cases In the 40-50 years of age group- 10.5% of cases accounted for the remaining coronal tooth structure of 2-4mm. In male patients, 43.7% of cases and in the female patients, 28.2% of cases accounted for the remaining coronal tooth structure of 2-4mm. In the first quadrant, 19.25% of cases, In the second quadrant, 15.4% of cases, In the third quadrant, 17.36% of cases and In the fourth quadrant, 20.2% of cases accounted for the remaining coronal tooth structure of 2-4mm.

Among the 83 maxillary molars, 11 teeth have been noted of having remaining coronal tooth structure of 1-2mm, 68 teeth have been noted of having remaining coronal tooth structure of 2-4mm, 4 teeth have been noted of having remaining coronal tooth structure of 4-6mm. Among the 136 mandibular molars, 31 teeth have been noted of having remaining coronal tooth structure of 1-2mm, 98 teeth have been noted of having remaining coronal tooth structure of 2-4mm, 7 teeth have been noted of having remaining coronal tooth structure of 4-6mm.

Flowchart 1: Shows Total Number Of Cases And Cases Included Based On The Inclusion And Exclusion Criteria

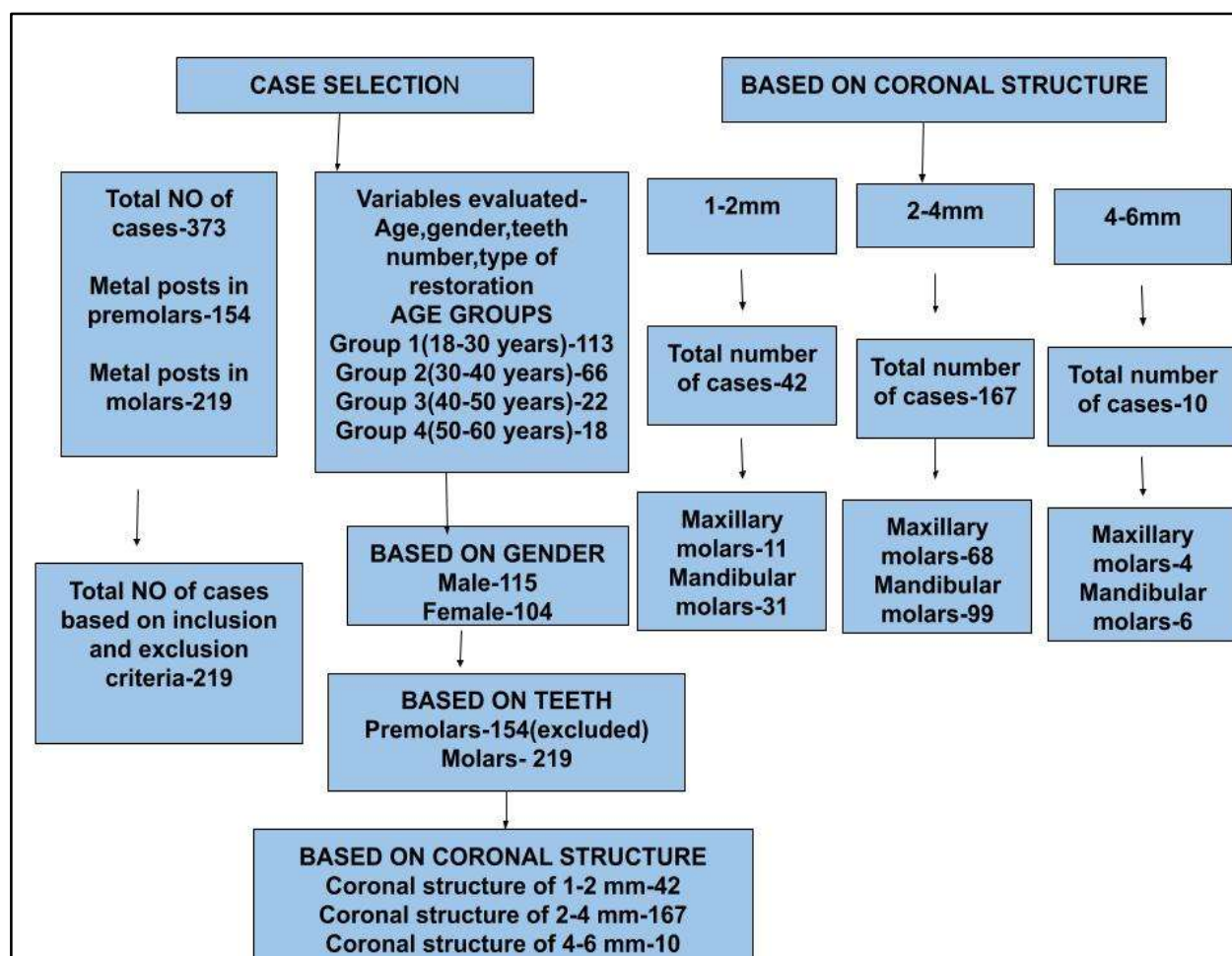


Table : 1 Patient Demographics

Patients Characteristics	No of Patients	Percentage value
Gender		
Male	115	52.5%
Female	104	47.5%
Age		
18- 30 years	113	51.6%
30- 40 years	66	30.1%
40- 50 years	22	9.6%
50- 60 years	18	8.7%
Remaining Coronal Tooth Structure		
1-2mm	42	19.2%
2-4mm	167	76.3%
4-6mm	10	4.6%

Table 1- showing distribution of cases which were included for the study based on Age and Gender. Maximum number of cases were reported in the age group of 18-30 years. Out of 373 cases, 52.5% were male patients, 47.5% were female patients.

Tooth Distribution	No of Teeth	Percentage value
Jaw		
Maxillary	83	37.9%
Mandibular	136	62.1%

Teeth		
Posterior	219	99.7%
Molars	219	99.7%

Table 2- Showing distribution of cases which were included for the study based on teeth type. Out of 373 cases, maxillary molars accounted for 37.9% of cases and mandibular molars accounted for 62.1% cases.

Age group	Frequency	Percent	Valid percent	Cumulative percent
1	113	50.4	50.7	50.7
2	66	30.8	30.9	81.6
3	22	9.2	9.2	85.3
4	18	9.1	9.1	100
Gender	Frequency	Percent	Valid percent	Cumulative percent
Female	106	47.3	47.5	47.5
Male	117	52.2	52.5	100.0
Teeth number	Frequency	Percent	Valid Percent	Cumulative percent
First quadrant	42	18.8	18.8	18.8
Second quadrant	42	18.8	18.8	37.7
Third quadrant	67	29.9	30.0	67.7
Fourth quadrant	72	32.1	32.3	100.0
Coronal structure	Frequency	Percent	Valid percent	Cumulative percent

1-2mm	42	18.8	19.2	19.2
2-4mm	167	74.6	76.3	95.4
4-6mm	10	4.5	4.6	100

Table 3: Showing distribution of frequency among Age, Gender, Teeth number and Remaining Coronal Tooth Structure

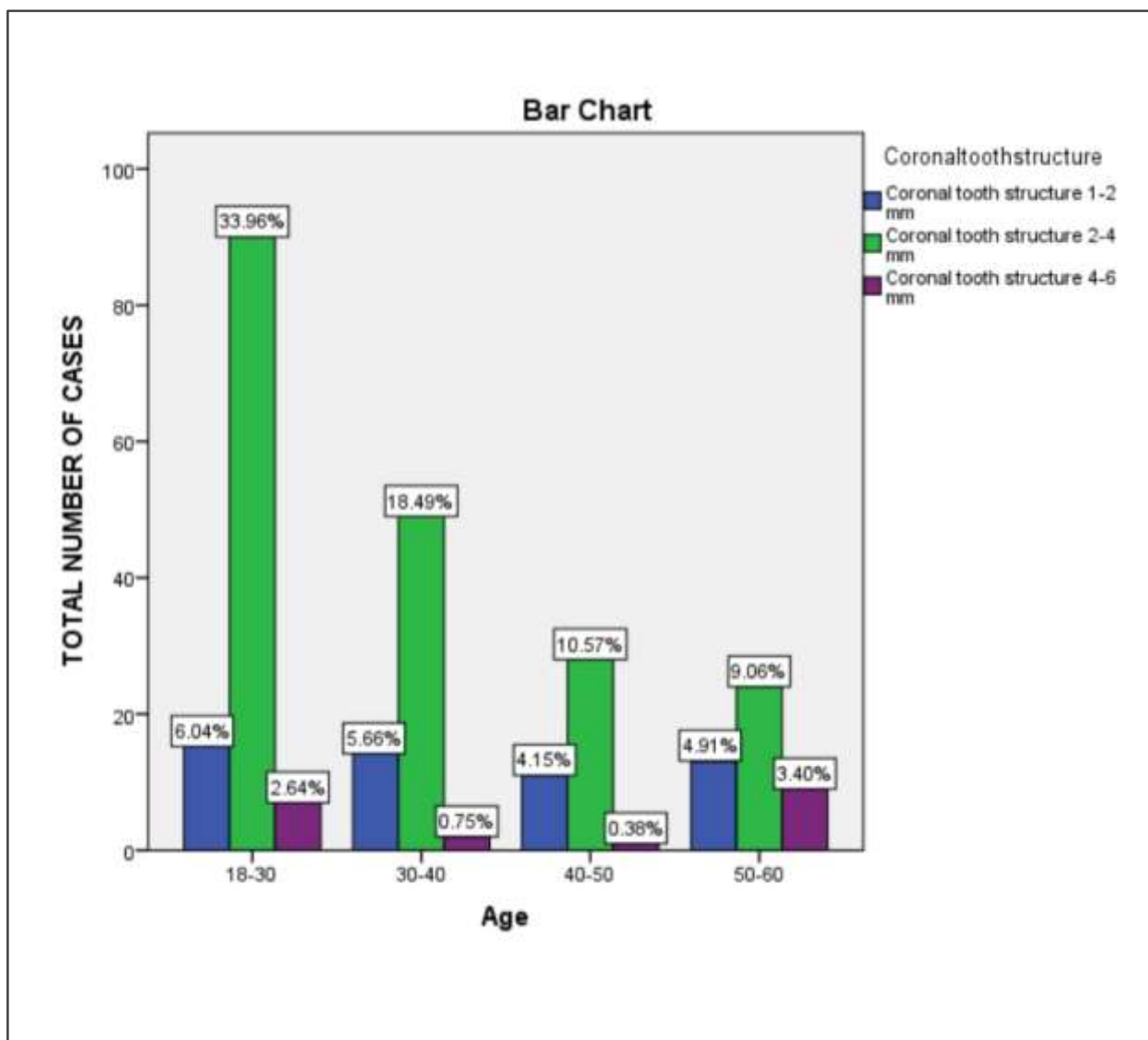


Chart 1: Bar chart showing the association between age and remaining coronal tooth structure in prefabricated metal posts, X axis represents the age group of the patient, Y axis represents the remaining coronal tooth structure; Based on the age of the patients, maximum cases accounted for the remaining coronal tooth structure of 2-4mm. However, this is statistically not significant (Chi Square test-2.207, p value 0.06>0.05) (Table 3)

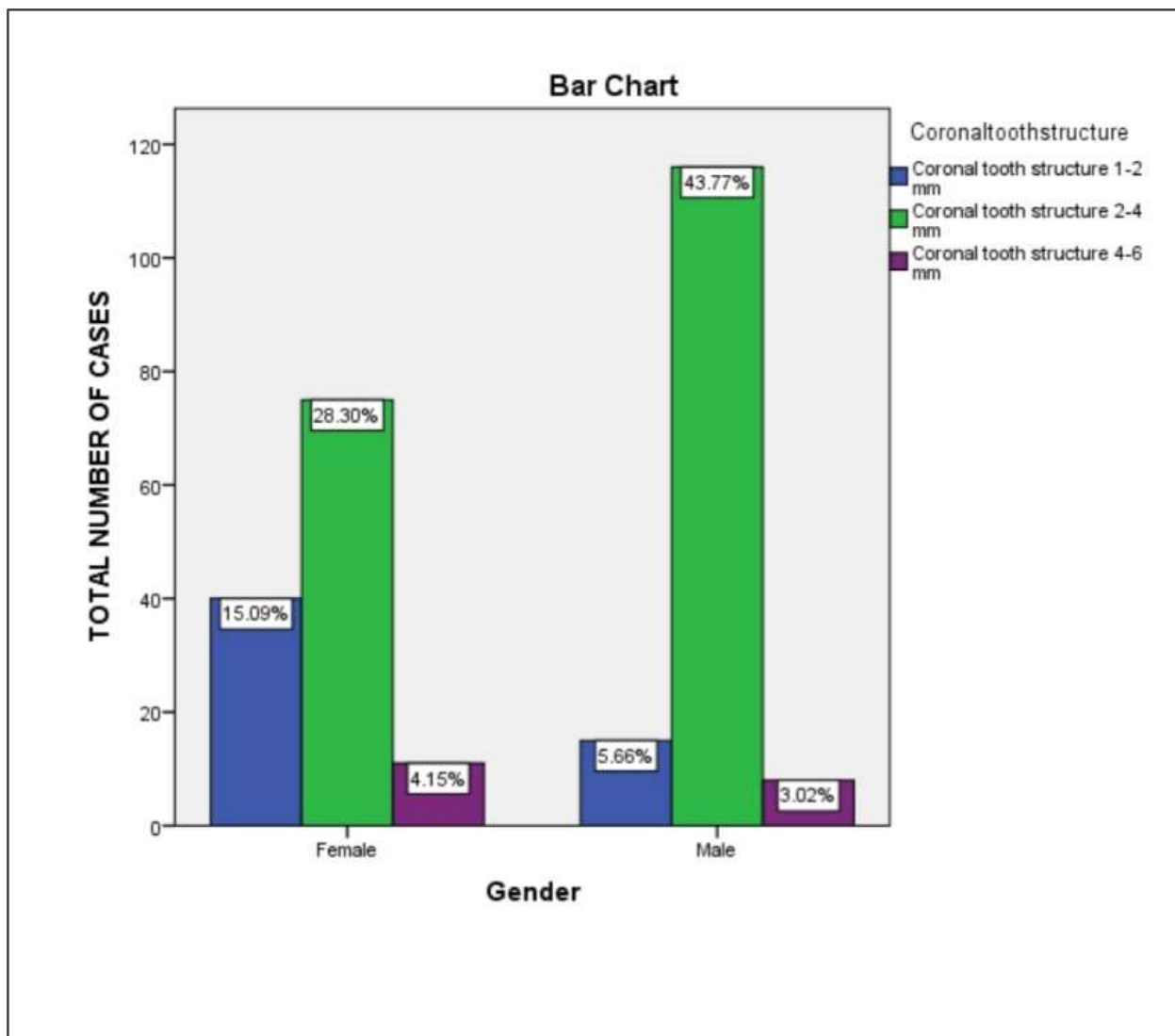


Chart 2: Bar chart showing the association between gender and remaining coronal tooth structure in prefabricated metal posts, X axis represents the gender of the patient, Y axis represents the remaining coronal tooth structure; Based on gender, maximum cases accounted for the remaining coronal tooth structure of 2-4mm. However, this is statistically not significant (Chi Square test-2.847, p value is 0.32>0.05) (Table 3).

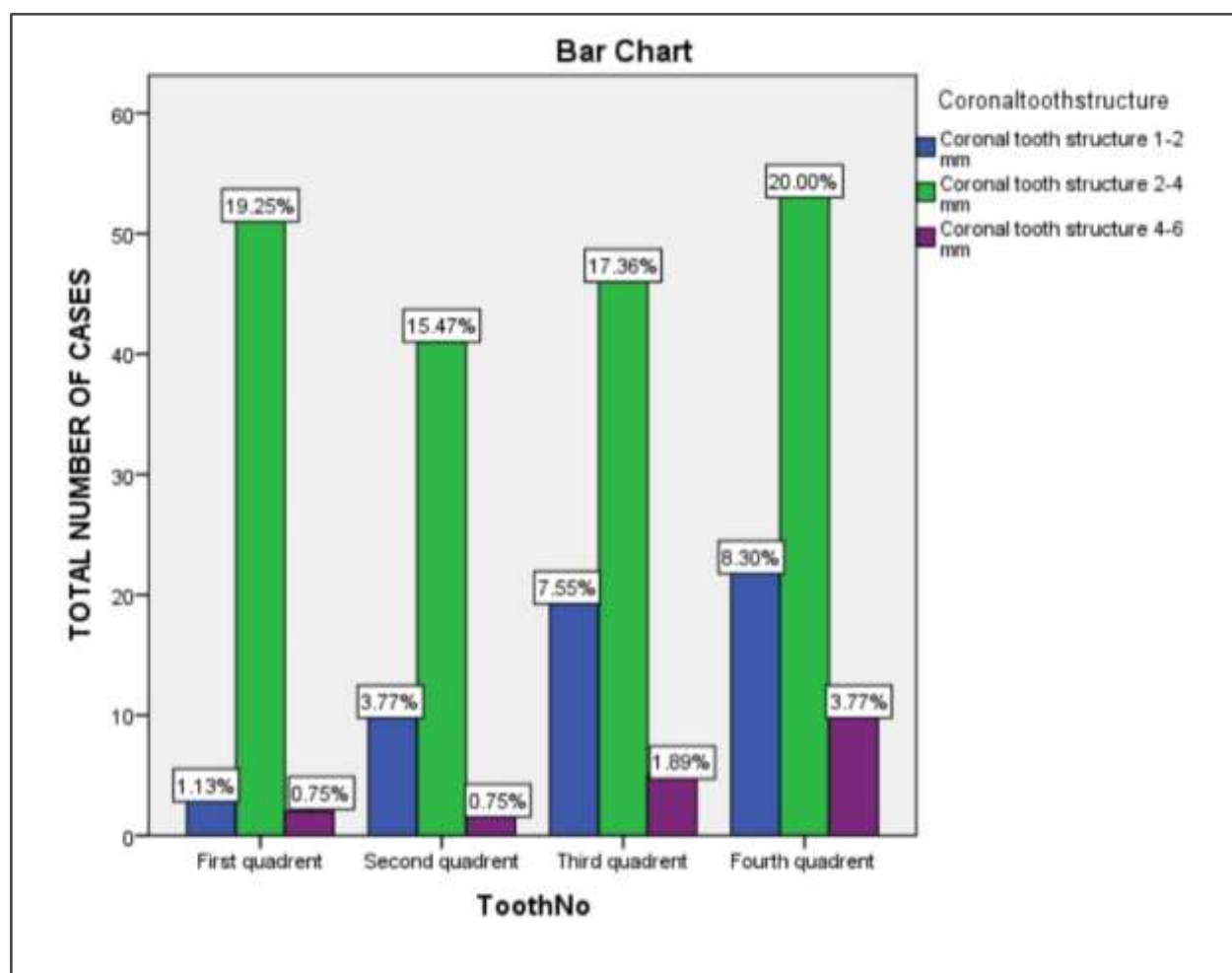


Chart 3: Bar chart Showing the association between teeth and remaining coronal tooth structure in prefabricated metal posts, X axis represents the teeth number of the patient and Y axis represents the remaining coronal tooth structure; Based on teeth, maximum cases in molars accounted for the remaining coronal tooth structure of 2-4mm. However, this is statistically not significant.(Chi Square test-2.088, p value is 0.35>0.05)

DISCUSSION

The choice of an appropriate restorative technique is essential for endodontically treated teeth as it is more susceptible to fracture often. Thus, post and core is often indicated. An important key factor in selecting the post is by assessing the remaining coronal tooth structure.

Jung found that there was no statistically significant difference found in the survival rate between cobalt chrome cast posts and prefabricated titanium posts after 10 year follow up. Regardless of type of post, the survival rate was 83% after a follow up of 10 years was reported in many studies [16,17]. An important finding that can be gained by assessing the remaining coronal tooth structure is survival rate.

Fokkings in 2007 performed a 17 year long term clinical study, analysing survival of different metal post and core restoration with covering crown as well as post free all composite core restoration. The results showed no influence of type of post and core restoration on survival probability [17]. The survival rates at tooth level varied from 83-92% corresponding with those obtained in many studies. In this way, parallel/ serrated, parallel/ threaded posts have been described as the most retentive systems.

The failure rate was higher for women (27% vs 16%). On the contrary, Torbjorner registered a significant higher failure rate for men. The contributing factors to this greater failure rate were thought to be higher occlusal forces. Maxillary premolars presented the highest failure rates[18]. Jung reported that maxillary premolars presented higher failure rates in a study comparing two types of metallic posts - prefabricated titanium posts with composite resin cores, golden alloy cast posts and cores[19]. Failure and survival rate cannot be calculated in this study as it was a retrospective analysis of one year.

The complications after post and core restorations were loss of retention (dislodgement with posterior/ in need of re cementation); insertion of new post and core (re restoration); root fracture or caries and need of apical surgery. Increased mobility due to periodontal problems were also included[20].

44% of teeth restored with post and core presented with either restorative, endodontic/ periodontal complications. The most frequent of all was the dislodgement of this post, root fracture and caries- more common in teeth with prefabricated post[21]. Although dislodgement of post is less noted in metal post compared to other post systems.

Soransen,2009 found that 25-85% of endodontically treated teeth were extracted due to incorrect restorative procedure. Loss of retention was the most frequent complication. Soransen ascertained that a tapered post could act as a wedge and fracture the tooth during function. Parallel sided posts apparently induce less stress on the root, therefore less prone to fracture[3].

Assif concluded in a study conducted using posts,that the post design had no influence on resistance to fracture[22,23]. Screw posts presented higher resistance to tensile than cemented posts in vitro and they also produce more stress increasing the risk of root fracture.

The influence of remaining coronal structure on the survival of root canal filled teeth has been noted to be at greater extent.Finally among the multiple factors that have influenced the prognosis of restorations with posts, excessive removal of root dentin when preparation decreases resistance to fracture and it should be avoided.It is similar to many factors that influence the endodontic therapy such as proper disinfection, shaping, placement of intracanal medicament[24–29].Similarly, many factors influence the vital status of pulp in case of inflammation, traumatic injury,calcified canal[30,31].The pulpal diagnosis should be made properly with advanced armamentarium[32,33].

Many luting cements used for post and core cementation have many advantages such as aesthetic property[34,35], proper adaptation of the post to the walls.

Many endodontically treated molars do not require a post because they have more tooth substance and a larger pulp chamber to retain a core buildup.When a post is required as a result of extensive loss of natural tooth substance, it should be placed in the largest and straightest canal to avoid weakening the root too much during post space preparation and root perforation in curved canals. The distal canal of mandibular molars and the palatal canal of maxillary molars usually are the best canals for post placement. When core retention still is insufficient after a single post is inserted, placement of pins can be considered for additional retention[36].

Overall consensus was an agree with the findings of the study. The limitations of this study confined to the smaller number of population and it was done in endodontically treated molars only. For arriving at conclusion

for posterior teeth, premolars should also be included. Future studies should be done in larger populations and it can also be done in premolars.

CONCLUSION

A remaining coronal tooth structure of 2-4 mm was noted in greater levels than the other levels in endodontically treated molars which received with prefabricated metal posts although it's not statistically significant. 2-4mm of remaining coronal tooth structure is essential for preventing root fracture, post dislodgement and fracture.

Declaration of patient consent

The authors certify that they have obtained all appropriate patient consent forms. In the form, the patient(s) has/have given his/her/their consent for his/her/their images and other clinical information to be reported. The patients understand that their names and initials will not be published and due efforts will be made to conceal their identity, but anonymity cannot be guaranteed.

AUTHOR CONTRIBUTIONS

Keerthana T, author 1 Writing - Original Draft Preparation; Sindhu Ramesh, Author 2 -Review and Editing; Deepak .S, author 3- Review.

ACKNOWLEDGEMENT

With Sincere gratitude , we acknowledge the staff members of the department of Conservative Dentistry and Endodontics and Saveetha Dental College and study participants for their extended support towards the completion of research.

CONFLICTS OF INTEREST

There are no conflicts of interest.

REFERENCES

1. Peroz I, Blankenstein F, Lange K-P, Naumann M. Restoring endodontically treated teeth with posts and cores--a review. *Quintessence Int.* 2005 Oct;36(9):737-46.
2. Fokkinga WA, Kreulen CM, Bronkhorst EM, Creugers NHJ. Up to 17-year controlled clinical study on post-and-cores and covering crowns. *J Dent.* 2007 Oct;35(10):778-86.
3. Mentink AG, Meeuwissen R, Käyser AF, Mulder J. Survival rate and failure characteristics of the all metal post and core restoration. *J Oral Rehabil.* 1993 Sep;20(5):455-61.
4. Schwartz RS, Robbins JW. Post placement and restoration of endodontically treated teeth: a literature review. *J Endod.* 2004 May;30(5):289-301.
5. Bergman B, Lundquist P, Sjögren U, Sundquist G. Restorative and endodontic results after treatment with cast posts and cores. *J Prosthet Dent.* 1989 Jan;61(1):10-5.
6. Goodacre CJ, Bernal G, Rungcharassaeng K, Kan JYK. Clinical complications in fixed prosthodontics

[Internet]. Vol. 90, The Journal of Prosthetic Dentistry. 2003. p. 31–41. Available from: [http://dx.doi.org/10.1016/s0022-3913\(03\)00214-2](http://dx.doi.org/10.1016/s0022-3913(03)00214-2)

7. Sorensen JA, Martinoff JT. Endodontically treated teeth as abutments. *J Prosthet Dent*. 1985 May;53(5):631–6.

8. Juloski J, Radovic I, Goracci C, Vulicevic ZR, Ferrari M. Ferrule effect: a literature review. *J Endod*. 2012 Jan;38(1):11–9.

9. de Oliveira JA, Pereira JR, Lins do Valle A, Zogheib LV. Fracture resistance of endodontically treated teeth with different heights of crown ferrule restored with prefabricated carbon fiber post and composite resin core by intermittent loading. *Oral Surg Oral Med Oral Pathol Oral Radiol Endod*. 2008 Nov;106(5):e52–7.

10. Nasim I, Hussainy S, Thomas T, Ranjan M. Clinical performance of resin-modified glass ionomer cement, flowable composite, and polyacid-modified resin composite in noncarious cervical lesions: One-year follow-up [Internet]. Vol. 21, Journal of Conservative Dentistry. 2018. p. 510. Available from: http://dx.doi.org/10.4103/jcd.jcd_51_18

11. Nandakumar M, Nasim I. Comparative evaluation of grape seed and cranberry extracts in preventing enamel erosion: An optical emission spectrometric analysis. *J Conserv Dent*. 2018 Sep;21(5):516–20.

12. Rajendran R, Kunjusankaran RN, Sandhya R, Anilkumar A, Santhosh R, Patil SR. Comparative Evaluation of Remineralizing Potential of a Paste Containing Bioactive Glass and a Topical Cream Containing Casein Phosphopeptide-Amorphous Calcium Phosphate: An in Vitro Study [Internet]. Vol. 19, Pesquisa Brasileira em Odontopediatria e Clínica Integrada. 2019. p. 1–10. Available from: <http://dx.doi.org/10.4034/pboci.2019.191.61>

13. Fernandes AS, Shetty S, Coutinho I. Factors determining post selection: a literature review. *J Prosthet Dent*. 2003 Dec;90(6):556–62.

14. Sidoli GE, King PA, Setchell DJ. An in vitro evaluation of a carbon fiber-based post and core system. *J Prosthet Dent*. 1997 Jul;78(1):5–9.

15. Stockton LW, Williams PT. Retention and shear bond strength of two post systems. *Oper Dent*. 1999 Jul;24(4):210–6.

16. Du J-K, Lin W-K, Wang C-H, Lee H-E, Li H-Y, Wu J-H. FEM analysis of the mandibular first premolar with different post diameters. *Odontology*. 2011 Jul;99(2):148–54.

17. Heydecke G, Butz F, Strub JR. Fracture strength and survival rate of endodontically treated maxillary incisors with approximal cavities after restoration with different post and core systems: an in-vitro study. *J Dent*. 2001 Aug;29(6):427–33.

18. Al-Wahadni AM, Hamdan S, Al-Omiri M, Hammad MM, Hatamleh MM. Fracture resistance of teeth restored with different post systems: in vitro study. *Oral Surg Oral Med Oral Pathol Oral Radiol Endod*. 2008 Aug;106(2):e77–83.

19. Hazzaa M, Elguindy J, Alagroudy M. Fracture resistance of weakened roots restored with different types of posts. *Life Sci J* [Internet]. 2015;12(10). Available from: http://www.lifesciencesite.com/lscj/life121015/014_29522life121015_113_118.pdf

20. Balkenhol M, Rupf S, Laufersweiler I, Huber K, Hannig M. Failure analysis and survival rate of post and core restorations under cyclic loading [Internet]. Vol. 44, International Endodontic Journal. 2011. p. 926–37. Available from: <http://dx.doi.org/10.1111/j.1365-2591.2011.01901.x>

21. Boone K, Murchison D, Schjndler W, Walkeriii W. Post Retention: The Effect of Sequence of Post-Space Preparation, Cementation Time, and Different Sealers [Internet]. Vol. 27, Journal of Endodontics. 2001. p. 768–71. Available from: <http://dx.doi.org/10.1097/00004770-200112000-00014>

22. Kıvanç BH, Alaçam T, Ulusoy ÖİA, Genç Ö, Görgül G. Fracture resistance of thin-walled roots restored with different post systems. *Int Endod J.* 2009;42(11):997–1003.
23. Akkayan B, Gülmez T. Resistance to fracture of endodontically treated teeth restored with different post systems. *J Prosthet Dent.* 2002 Apr;87(4):431–7.
24. Ramamoorthi S, Nivedhitha MS, Divyanand MJ. Comparative evaluation of postoperative pain after using endodontic needle and EndoActivator during root canal irrigation: A randomised controlled trial. *Aust Endod J.* 2015 Aug;41(2):78–87.
25. Siddique R, Sureshababu NM, Somasundaram J, Jacob B, Selvam D. Qualitative and quantitative analysis of precipitate formation following interaction of chlorhexidine with sodium hypochlorite, neem, and tulsi. *J Conserv Dent.* 2019 Jan;22(1):40–7.
26. Noor SSSE, S Syed Shihaab, Pradeep. Chlorhexidine: Its properties and effects [Internet]. Vol. 9, *Research Journal of Pharmacy and Technology.* 2016. p. 1755. Available from: <http://dx.doi.org/10.5958/0974-360x.2016.00353.x>
27. Manohar MP, Sharma S. A survey of the knowledge, attitude, and awareness about the principal choice of intracanal medicaments among the general dental practitioners and nonendodontic specialists. *Indian J Dent Res.* 2018 Nov;29(6):716–20.
28. Ramanathan S, Solete P. Cone-beam Computed Tomography Evaluation of Root Canal Preparation using Various Rotary Instruments: An in vitro Study. *J Contemp Dent Pract.* 2015 Nov 1;16(11):869–72.
29. Teja KV, Ramesh S. Shape optimal and clean more. *Saudi Endodontic Journal.* 2019 Sep 1;9(3):235.
30. Kumar D, Delphine Priscilla Antony S. Calcified Canal and Negotiation-A Review [Internet]. Vol. 11, *Research Journal of Pharmacy and Technology.* 2018. p. 3727. Available from: <http://dx.doi.org/10.5958/0974-360x.2018.00683.2>
31. Rajakeerthi R, Ms N. Natural Product as the Storage medium for an avulsed tooth--A Systematic Review. *Cumhuriyet Dental Journal.* 2019;22(2):249–56.
32. Teja KV, Ramesh S, Priya V. Regulation of matrix metalloproteinase-3 gene expression in inflammation: A molecular study. *J Conserv Dent.* 2018 Nov;21(6):592–6.
33. Janani K, Palanivelu A, Sandhya R. Diagnostic accuracy of dental pulse oximeter with customized sensor holder, thermal test and electric pulp test for the evaluation of pulp vitality - An in vivo study [Internet]. Vol. 23, *Brazilian Dental Science.* 2020. Available from: <http://dx.doi.org/10.14295/bds.2020.v23i1.1805>
34. Jose J, Subbaiyan H. Different Treatment Modalities followed by Dental Practitioners for Ellis Class 2 Fracture—A Questionnaire-based Survey. *Open Dent J* [Internet]. 2020; Available from: <https://opendentistryjournal.com/VOLUME/14/PAGE/59/FULLTEXT/>
35. Ravinthar K, Jayalakshmi. Recent Advancements in Laminates and Veneers in Dentistry [Internet]. Vol. 11, *Research Journal of Pharmacy and Technology.* 2018. p. 785. Available from: <http://dx.doi.org/10.5958/0974-360x.2018.00148.8>
36. Souza EM, do Nascimento LM, Maia Filho EM, Alves CMC. The impact of post preparation on the residual dentin thickness of maxillary molars. *J Prosthet Dent.* 2011 Sep;106(3):184–90.
37. Farhat Yaasmeen Sadique Basha, Rajeshkumar S, Lakshmi T, Anti-inflammatory activity of *Myristica fragrans* extract . *Int. J. Res. Pharm. Sci.,* 2019 ;10(4), 3118-3120 DOI: <https://doi.org/10.26452/ijrps.v10i4.1607>