

# STUDY ON OCCURRENCE AND MANAGEMENT OF ALVEOLAR OSTEITIS

Type of manuscript: Research article

Running title: Awareness on occurrence and management of alveolar osteitis.

Pathmashri.V. P<sup>1</sup>, Dinesh Kumar<sup>2</sup>, Dhanraj Ganapathy<sup>3</sup>

**Abstract:** A dry socket also referred to as alveolar osteitis is a postoperative complication that interferes with the healing process that takes place after a tooth extraction. "Dry socket" was first described by Crawford in 1896. It occurs when the tooth socket loses the blood clot that forms after the tooth is extracted and the bone inside the socket is exposed. It occurs in 0.5-5% of routine dental extractions and 25-30% in extraction of impacted mandibular third molars. Clinically, an empty socket which lacks a blood clot and exposed bone are seen. The socket may be filled with food debris and saliva mixture. Pain starts 24-72 hours after extraction. It varies in frequency and intensity and radiates to the ear and neck. It is not characterized by redness, swelling, fever or pus formation but edema of the surrounding gingiva and regional lymphadenitis is present. Histological features of dry socket are remnants of the blood clot and a massive inflammatory response characterized by neutrophils and lymphocytes which may extend into the surrounding alveolus.

**Keywords:** Dry socket, Alveolar osteitis, Extraction, Surgery, Dental

---

## 1. INTRODUCTION:

Alveolar osteitis is a painful dental condition that sometimes happens after the removal of a permanent tooth. It is commonly known as Dry Socket. It is the most common complication of tooth extraction which is associated with pain due to inflammatory reaction seen in the exposed walls of the extracted tooth socket caused due to dislodgment of the blood clot from the extracted tooth socket [1]. In other words, it is caused post extraction where all the socket bone or some of it within or around the socket is exposed. This occurs when the initial blood clot formed is dislodged or a layer of healing, vital epithelium is not covering it. With the bone being exposed the patient will not be able to prevent food particles or the tongue touching the exposed bone causing acute pain due to mechanical stimulus. The pain is acute and frequent.

Once the blood clots is dislodged and there is accumulation of food particles there is interruption in formation of blood clot again and these food particle attract bacteria leading the fermentation of the food particles and toxins are released this may irritate the bone, cause foul smell or halitosis and foul taste [2]. Dry socket is more common in females than in males which is related to the influence of hormonal changes which occurs normally or can also be due to oral contraceptives taken by the female. When a tooth is extracted there is pain and discomfort, this will lessen over time since the patient will

<sup>1</sup>Undergraduate student, Saveetha Dental College, Saveetha Institute of Medical and Technical Sciences, Chennai, India

<sup>2</sup>Senior Lecturer, Department of Oral Surgery, Saveetha Dental College, Saveetha Institute of Medical and Technical Sciences, Chennai, India, Email: shrroom555@gmail.com

<sup>3</sup>Professor and Head, Department of Prosthodontics, Saveetha Dental college, Saveetha Institute of medical and technical science, 162, Poonamallee High Road, Chennai 600077, Tamil Nadu, India, Email: dhanraj@saveetha.com

Corresponding author: Dhanraj Ganapathy,

Professor and Head, Department of Prosthodontics, Saveetha Dental college, Saveetha Institute of medical and technical science, 162, Poonamallee High Road, Chennai 600077, Tamil Nadu, India, Email: dhanraj@saveetha.com

be under medication. But if the discomfort persists and pain becomes acute in addition to halitosis, etc. the incidence of dry socket can range from being 3% for routine extractions to 30% post extraction of a mandibular third molar [3].

The occurrence of alveolar osteitis can be due to a lot of factors including difficult, prolonged and traumatic extractions, pre-operative infections at the site of extraction, bone disorders in maxilla or mandible, systemic illness, smoking, oral contraceptives, if the patient is under any oral contraceptives or anti-coagulants also if the patient is not following post extraction instructions.

For the treatment of dry socket dentists prescribe antibiotics and analgesics. Along with salt water rinses at least twice a day or more, the socket can be debrided off the food debris under local anaesthesia, soft dressing which is putting a medicated gauze in the socket is done to ease the pain, extra oral swelling caused due to dry socket can be eased applying ice pack. Patient must follow the post-operative instructions which are as follows; patient must give the dentist their full medical history, if gauze is provided at the site of extraction do not remove it for a good 30 mins, applying a good pressure over the gauze, do not rinse mouth, do not spit, do not use straws to drink, ice packs massages in case of swellings, do not smoke or drink alcohol, good to drink something very cold or eat a ice cream to accelerate the clot formation. If severe bleeding persists even after 24 hrs of extraction at the extraction site please visit the dentist. Must take the prescribed medications. Patients can use salt in warm water and use it to rise every few hours after 24 -48 hours of extraction, also best to avoid spicy and hot food and continue with soft foods and at last the pain is expected to stay for at least 10-14 days in case of wisdom tooth extraction. In this survey the knowledge of dental students on occurrence and management of alveolar osteitis are analyzed through a questionnaire, which consists of 10 questions in total. 7 questions were True or False questions and the rest were multiple choice questions.

## **2. Materials and Method:**

A cross sectional study was conducted among 100 randomly selected dental students who were in their third year, final year or doing their internship in dental school, attending a private dental college in Chennai. A self-structured questionnaire was used to assess the knowledge of the participants based on their knowledge on alveolar osteitis, aetiology, its clinical features on oral cavity, diagnosis and treatment. Most of the questions were true or false type questions.

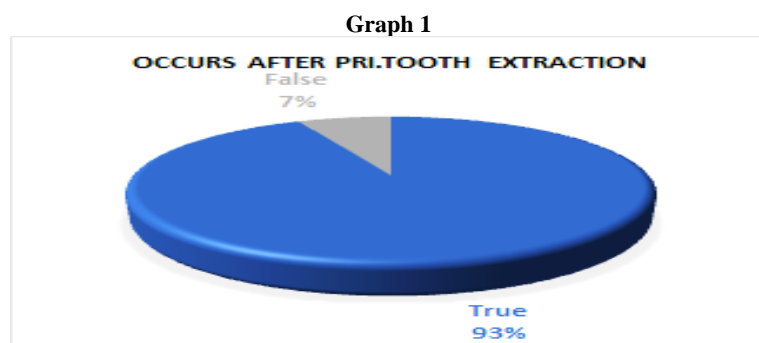
## **3. Questionnaire**

- 1) Dry socket doesn't occur when a primary tooth is extracted. True or False
- 2) Alveolar osteitis occurs immediately after extraction. True or false
- 3) Dry is caused due to dislodgement of blood clot from the extracted socket. True or False
- 4) Alveolar osteitis occurs when the extracted tooth socket gets infected and inflamed. True or False
- 5) It is more common in maxilla than mandible. True or False
- 6) Excessive force applied to the tooth causing burnishing of bony walls and crushed blood vessels leading to impaired repair process. True or False
- 7) Signs and symptoms seen are
  - Pain
  - Bare bone

- Pus discharge
  - Infected and inflamed socket
- 8) Onset of symptoms seen
- Immediately after extraction
  - 24 hours after extraction
  - 48 hours after extraction
  - 72 hours after extraction
- 9) Management of dry socket includes
- Irrigation
  - NSAIDs
  - Zinc oxide eugenol dressing
  - All of the above
- 10) An obtundent dressing is important to prevent further irritation due to food impaction. True or False

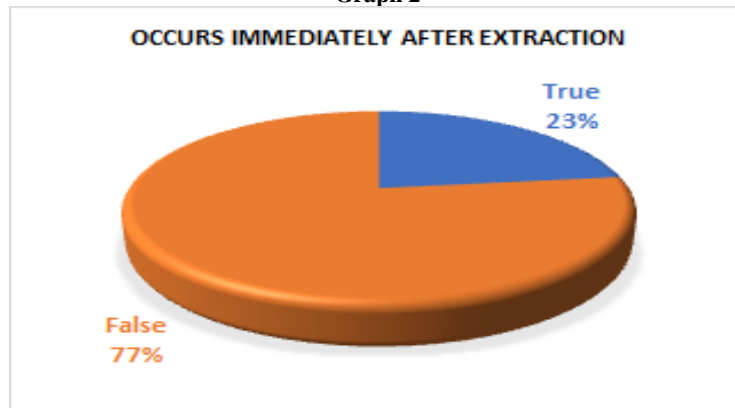
#### 4. Results and Discussion:

Dry socket is the most studied and researched complications to find an effective and safe method for treatment and prevention [4]. The first question in the question is about the occurrence of dry socket after primary tooth extraction. 93% of the participants answered true referring that dry socket does not occur after extraction of primary teeth. Illustrated in graph 1. For the question dry socket occurs immediately after extraction 77% answered false and the rest 23% answered true and is represented in graph 2. The next question was about the cause of alveolar osteitis, “dry socket occurs due to blood clot dislodgement”. 87% of the participants answered true as answer and 13% answered false [graph 3]. Next question was whether an infected and inflamed socket causes dry socket 80% of the participants answered false and the rest 20 % answered true [graph 4].



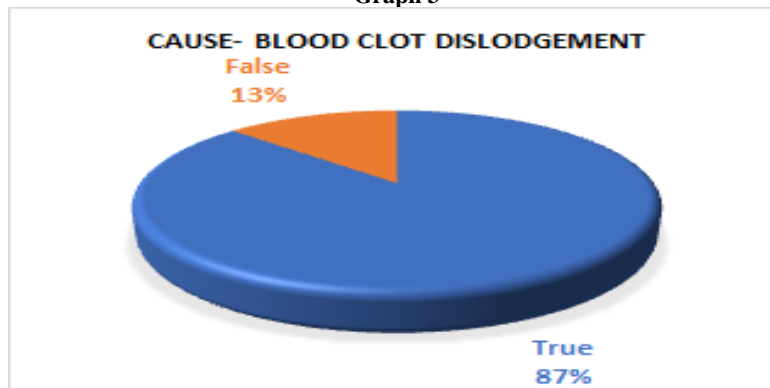
The first question was about the occurrence of dry socket after primary tooth extraction. 93% of the participants answered true referring that dry socket does not occur after extraction of primary teeth. Rest 7% of the participants were wrong since they selected false.

**Graph 2**



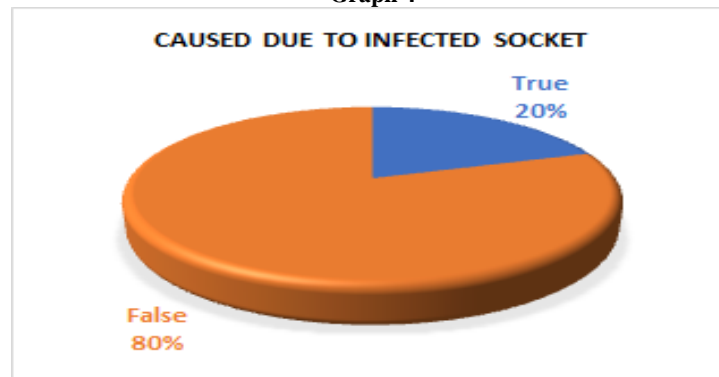
For the question about dry socket occurring immediately after extraction 77% answered false and the rest 23% answered true and is represented in graph 2. Dry socket does not occur immediately after extraction. Dry socket occurs once the blood clot sealing the socket bone from the external surface gets dislodged leading to bare bone. This causes pain, food debris accumulation, swelling, etc.

**Graph 3**



This question was about the cause of alveolar osteitis, “dry socket occurs due to blood clot dislodgement”. 87% of the participants answered true as answer and 13% answered false. Alveolar osteitis or dry socket occurs due to blood clot dislodgement. This loss of clot can be due to a lot of reasons like loss of clot while rinsing mouth or systemic disease , smoking , alcohol , hormonal imbalances which disturbs the formation of clot itself.

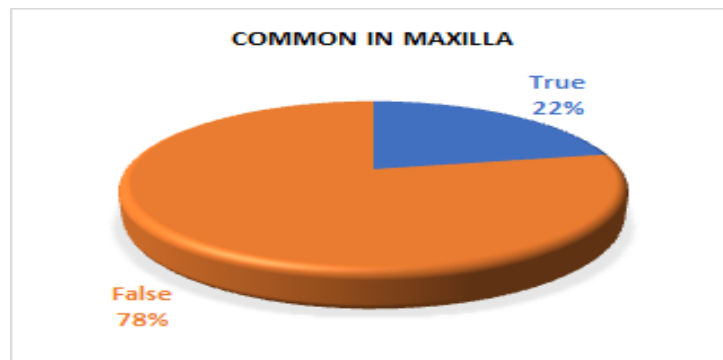
**Graph 4**



The question was whether an infected and inflamed socket causes dry socket 80% of the participants answered false and the rest 20 % answered true. An already pre-existing infection or lesion before extraction does affect the formation of

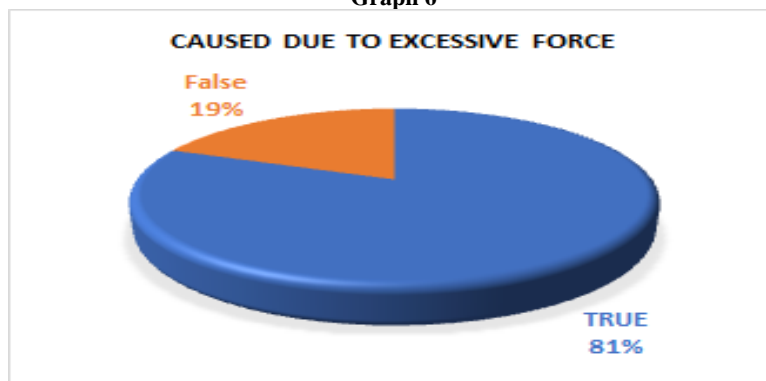
blood clot and healing but doesnot cause dry socket in particular. But a dry socket can get infected due to food debris causing further increase in pain and swelling.

**Graph 5**



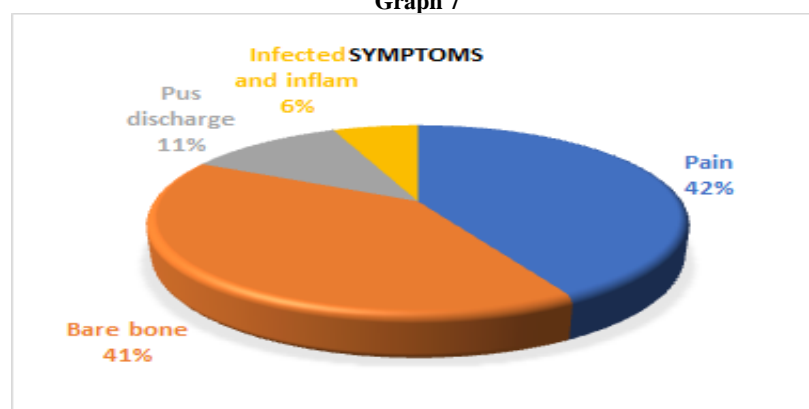
For the question about the common site of occurrence 78% answered maxilla is not the common site of occurrence and 22% this statement was false. Mandibular third molar is the most common site of dry socket occurrence. Maxilla is affected but comparatively less.

**Graph 6**



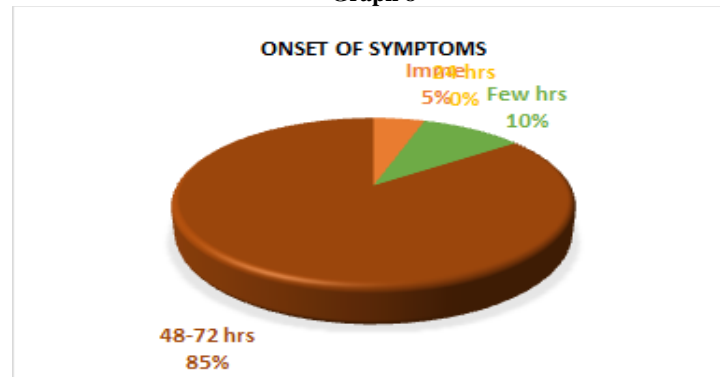
81% of the participants answered true for the question dry socket is caused due to excessive force applied during extraction rest 19% answered false. One of the reasons for occurence of dry socket is traumatic, difficult and prolonged extraction of the tooth. 81% of the participants were right for answering excessive force applied during extraction will cause dry socket since force can crush the socket wall bone also the blood vessels may ruptured leading to severe bleeding and inflammation.

**Graph 7**



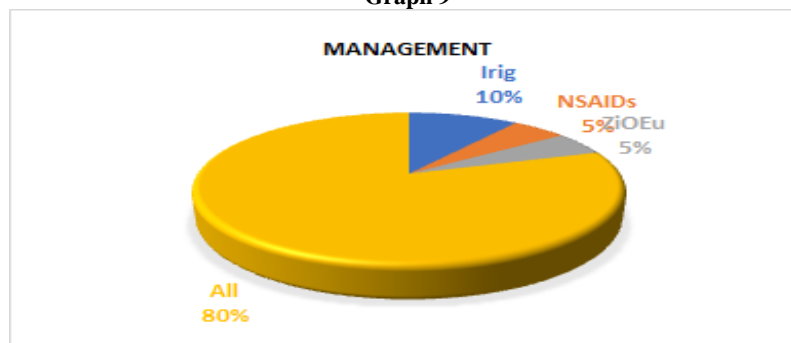
This question was a multiple-choice question. The question was 'signs and symptoms of dry socket' the options were pain, infection and inflammation, pus discharge, bare bone. 42% selected pain as 6% selected infection and inflammation, 11% selected pus discharge and 41% selected bare bone as answer. The right answer was bare bone and pain.

**Graph 8**



Next multiple-choice question was about when there was onset of symptoms. That is when does dry socket occur. The options were immediate after extraction, few hours after extraction, 48-72 hrs after extraction. 85% answered 48-72 hrs as answer, 10% answered after a few hours and 5% answered immediately. Dry socket occurs 2 to 3 days after extraction that is 48 to 72 days post extraction.

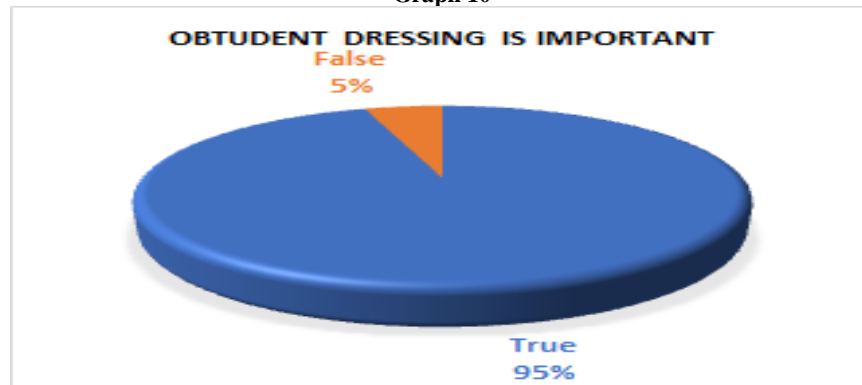
**Graph 9**



For the question about management of dry socket the options were irrigation, NSAIDs, ZnO Eugenol dressing, all the above. 80% selected all the above as the right answer, 10% selected irrigation, 5% selected NSAIDs, 5% selected as the answer. Irrigation, prescribing NSAIDs, zinc oxide eugenol dressing all are done for the management of dry sockets.

Irrigation calms down the pain and irritation, NSAIDs are anti-inflammatory and analgesic and zinc oxide eugenol dressing provides protection against further food debris deposition.

**Graph 10**



The final question was whether an obtundent dressing is important or not. 95% answered it is required and the rest 5% answered false. Obtundent dressing is nessesery. It is a procedure in which the socket is irrigated using warm saline and gauze soaked in iodoform along with eugenol or benzocaine is placed in the socket. 95% of the participants were right.

For the question about the common site of occurence 78% answered maxilla is not the common site of occurence and 22% this statement was false [graph 5]. 81% of the participants answered true for the question dry socket is caused due to excessive force applied during extraction rest 19% answered false [graph 6]. The next question was a multiple choice question. The question was 'signs and symptoms of dry socket' the options were pain, infection and inflammation, pus discharge, bare bone. 42% selected pain as 6% selected infection and inflammation, 11% selected pus discharge and 41% selected bare bone as answer. The right answer was bare bone and pain [graph 7].

Next multiple-choice question was about when there was onset of symptoms. The options were immediate after extraction, few hours after extraction, 48-72 hrs after extraction. 85% answered 48-72 hrs as answer, 10% answered after a few hours and 5% answered immediately [graph 8]. For the question about management of dry socket the options were irrigation, NSAIDs, ZnO Eugenol dressing, all the above. 80% selected all the above as the right answer, 10% selected irrigation, 5% selected NSAIDs, 5% selected as the answer [graph 9]. The final question was whether an obtundent dressing is important or not. 95% answered it is required and the rest 5% answered false [graph 10].

MS Fredric L. Bonine studied the effect of chlorhexidine rinse on the incidence of Alveolar osteitis in 371 patients for a period of three years, by comparing three groups. Group 1 no rinses, Group 2 post surgery peridex rinse twice daily for two weeks and Group 3 one rinse pre surgery and concluded that group two who had peridex rinse twice a day for two weeks post-surgery had a significant reduction in the occurrence of dry socket than the other two groups[5] . Prevalence of dry socket was significantly higher in smokers compared to non-smokers, was more prevalent in patients who underwent surgical extraction than non-surgical extraction and also the incidence was minimal when multiple teeth extraction than single extractions. This was the conclusion of the study by Nusair Y.M carried out in 469 patients (838 extractions) [6]. A similar study by Mohammed H Abu Younis in the year 2011 on the frequency, clinical picture and risk factors in a Palestinian dental teaching center concluded that, single tooth extractions, Trauma during surgery and smoking are the considerable predisposing factors in the occurrence of dry socket and also factors like medical history, sex, age, site of extraction, amount of anesthesia administered and experience of the operator has no effect on the incidence of dry socket [7].

The same type of study on the incidence and risk factors in Iranian population concluded that the incidence of dry socket was higher in people who are under oral contraceptives, menstrual cycle, smokers, difficulty of the surgery, length of

surgery and number of capsules used to reach anesthesia. Another study on clinical evaluation of dry socket in a Nigerian teaching hospital, among the 3319 extractions performed in 3008 patients only 136 cases were complicated by dry sockets[8]. A G Garcia studied if oral contraceptives used affect the occurrence of complications after mandibular third molar extraction and concluded that women under contraceptive pills had a higher risk of dry socket and also the oral contraceptive pills lowered the pain threshold leading to excess pain. The incidence of dry socket and oral contraceptives can be explained by the fibrinolytic effect of the pills which interferes with the blood clotting [9]. Another study on the effect of oral contraceptives in females on the incidence of alveolar osteitis after the extraction mandibular third molar suggested the oral contraceptive increases the incidence of dry socket on females undergoing surgical extraction [10]. A similar study by Ravi Bhujbal studied the effect of contraceptives in causing dry socket post extraction of mandibular third molar. In this study 987 mandibular third molar extractions were performed and 61 cases out of these reported back with dry socket. Out of this 43 were females. In this 43, 31 were under oral contraceptives and the rest 12 were not under any oral contraceptives. And concluded that oral contraceptive increases the incidence of dry socket, due to the fibrinolytic activity and presence of estrogen [11]. A study by Catellani JE on the effect of contraceptive cycle on localized alveolar osteitis stated that there is increased incidence of dry socket with the use of oral contraceptives which is due to increase in estrogen dose in the pills. The study concluded that the incidence of dry socket can be minimized by performing extractions on 23rd day to 28th day of the tablet cycle[12].

Maria Taberner reviewed the efficiency of different methods of management of dry socket and concluded that irrigation and curettage followed by zinc oxide eugenol dressing or plasma rich in growth factors will show better results by healing and pain reduction [13]. David R Goldman conducted a study on prevention of dry socket by application of linomycin in the localized area and concluded that the occurrence of dry socket reduced by 1.1% in gelfoam with linomycin when compared to gelfoam containing saline solution which was 7.8% [14]. A similar study comparing the gel foam containing Terra-Cortril Ophthalmic suspension placed in the mandibular third molar extraction site and it was seen that the incidence of the dry socket was 6.6% whereas in the control group with no terra-cortril suspension the incidence was 28.8% [15]. The basic treatment options for treating dry socket are irrigation of the surgical site and curettage to remove the debris followed by packing with zinc oxide eugenol paste on iodoform gauze to avoid further accumulation debris and food particles on the bone surface thus avoiding pain and discomfort. Additional chlorhexidine mouth rinses can be recommended [16].

## **5. Conclusion:**

Dry socket or Alveolar osteitis can be very painful conditions causing discomfort and extreme pain. The cause is undetermined since there is no one particular factor causing dry socket. Dry socket can become a complication post extraction due to factors like smoking, oral contraceptives taken by the patients, number of teeth extracted, etc. The main goal while treating dry socket would be relieving the pain by dressing to prevent insult of food debris and also bacterial growth. Treatment also includes irrigation with saline or chlorhexidine, curettage to remove or debride the debris followed by an obtundent dressing. Additional chlorhexidine mouthwashes can also be suggested. A regular follow up of the patient to ensure the healing process. A follow is more important if an obtundent dressing is placed.



## References:

1. Houston JP, McCollum J, Pietz D, Schneck D. Alveolar osteitis: a review of its etiology, prevention, and treatment modalities. *Gen Dent* 2002;50:457–63; quiz 464–5.
2. Blum IR. Contemporary views on dry socket (alveolar osteitis): a clinical appraisal of standardization, aetiopathogenesis and management: a critical review. *Int J Oral Maxillofac Surg* 2002;31:309–17.
3. Khawaja N, College of Dentistry, KSU, Riyadh, Parveen K, Almotreb A, et al. Survey of the Knowledge of Dry Socket and Management Among Dental Practitioners; Still Controversy? *Journal of the Pakistan Dental Association* 2019;28:192–6. <https://doi.org/10.25301/jpda.284.192>.
4. Heasman PA, Jacobs DJ. A clinical investigation into the incidence of dry socket. *British Journal of Oral and Maxillofacial Surgery* 1984;22:115–22. [https://doi.org/10.1016/0266-4356\(84\)90023-8](https://doi.org/10.1016/0266-4356(84)90023-8).
5. Nusair YM, Younis MHA. Prevalence, clinical picture, and risk factors of dry socket in a Jordanian dental teaching center. *J Contemp Dent Pract* 2007;8:53–63.
6. Abu Younis MH, Abu Hantash RO. Dry socket: frequency, clinical picture, and risk factors in a Palestinian dental teaching center. *Open Dent J* 2011;5:7–12.
7. Nejat AH, Eshghpour M. Dry socket following surgical removal of impacted third molar in an Iranian population: Incidence and risk factors. *Nigerian Journal of Clinical Practice* 2013;16:496. <https://doi.org/10.4103/1119-3077.116897>.
8. Oginni FO, Fatusi OA, Alagbe AO. A clinical evaluation of dry socket in a Nigerian teaching hospital. *J Oral Maxillofac Surg* 2003;61:871–6.
9. Garcia AG, Grana PM, Sampedro FG, Diago MP, Rey JMG. Does oral contraceptive use affect the incidence of complications after extraction of a mandibular third molar? *Br Dent J* 2003;194:453–5; discussion 445.
10. Xu J-L, Sun L, Liu C, Sun Z-H, Min X, Xia R. Effect of oral contraceptive use on the incidence of dry socket in females following impacted mandibular third molar extraction: a meta-analysis. *Int J Oral Maxillofac Surg* 2015;44:1160–5.
11. Bhujbal R, Sharma M, Patil V, Gawali N, Subedar RS. Effect of oral contraceptives in the incidence of dry socket after mandibular 3rd molar extraction: A prospective clinical study 2019.
12. Catellani JE, Harvey S, Erickson SH, Cherkin D. Effect of oral contraceptive cycle on dry socket (localized alveolar osteitis). *J Am Dent Assoc* 1980;101:777–80.
13. Taberner-Vallverdú M, Nazir M, Sánchez-Garcés MÁ, Gay-Escoda C. Efficacy of different methods used for dry socket management: A systematic review. *Med Oral Patol Oral Cir Bucal* 2015;20:e633–9.
14. Goldman DR, Kilgore DS, Panzer JD, Atkinson WH. Prevention of dry socket by local application of lincomycin in Gelfoam. *Oral Surg Oral Med Oral Pathol* 1973;35:472–4.
15. Tarakji B, Saleh LA, Umair A, Azzeghaiby SN, Hanouneh S. Systemic review of dry socket: aetiology, treatment, and prevention. *J Clin Diagn Res* 2015;9:ZE10.
16. Julius LL, Hungerford RW, Nelson WJ, McKercher TC, Zellhoefer RW. Prevention of dry socket with local application of Terra-Cortril in gelfoam. *J Oral Maxillofac Surg* 1982;40:285–6.