

KNOWLEDGE AND PRACTICE OF IMPRESSION TECHNIQUES FOR COMPLETE EDENTULOUS PATIENTS

Type of Research - Survey

Running Title: A survey on Impression Techniques

J.Aparna, Dr.SubhabrataMaiti, Dr. MP.Brundha, Dr.Jessy.P

ABSTRACT :

Impression making for completely edentulous patients is one of the critical factors in determining the success or failure of complete denture therapy. Precise reproduction of an edentulous foundation is essential for removable prosthesis retention, stability, and support. Evidence indicates that materials and methods differ in the way impressions are produced for complete dentures. An online survey involving 100 individuals by random sampling method which included Prosthodontics Postgraduates, Undergraduates, and General Practitioners from different locations in India after getting proper consent from the participants about various impression techniques performed for completely edentulous patients. The results were collected and then analyzed through SPSS software. Descriptive statistical analysis was carried out and the chi-square test was used and the p-value was calculated. This survey analysis has provided a clear view about the impression techniques and practices followed by Dental Practitioners in the process of taking an impression for completely edentulous patients which included theory followed during impression making, primary impression-tray, border molding material, primary and final impression material, border molding material, correction material, use of the custom tray, tissue stop, spacer, posterior palatal seal, flabby tissue and neutral zone for the taking of better impressions for completely edentulous patients. The present study about the knowledge and practice of impression techniques followed by Indian Dental Practitioners has provided a clear view about the current procedures undertaken by them and also provides a better view to improving certain procedures and techniques for the betterment of patients in future

Keywords :

Dental Practitioners; Impression Techniques; Custom Tray; Impression Material; Flabby Ridge.

I. INTRODUCTION :

A dental impression is a negative imprint of hard and soft tissues in the mouth from which it is possible to create a positive reproduction. Impression materials are designed to be liquid or semi-solid material which when first mixed and placed in the tray quickly set to a solid (usually a few minutes depending on the material), leaving an imprint of the structures of the mouth[1].

Impression making is an important step in making complete dentures for completely edentulous patients. Complete denture (CD) success depends primarily on impression accuracy which requires in-depth knowledge of denture bearing biomechanics and the properties of impression materials[2]. Complete impressions of the denture are considered to be one of the key factors in assessing success or failure for patients wearing CD. Accurate replication of the denture bearing

Saveetha Dental College, Saveetha Institute of Medical And Technical Sciences, Saveetha University 162, Poonamallee High Road, Chennai-600077, Tamil Nadu, India Mail id:151801042.sdc@saveetha.com Phone no: 9840710334, Senior Lecturer Department of Prosthodontics Saveetha Dental College, Saveetha Institute of Medical And Technical Sciences Saveetha University 162, Poonamallee High Road, Chennai-600077 Tamil Nadu, India Phone no:9007862704 Mail id: subhabratamaiti.sdc@saveetha.com, Associate Professor, Department of pathology, Saveetha Dental College, Saveetha Institute of Medical And Technical Sciences, Saveetha University, Email id: brundha.sdc@saveetha.com Phone no:9884421482 Senior Lecturer, Department of Pedodontics, Saveetha Dental College, Saveetha Institute of Medical And Technical Sciences, Saveetha University 162, Poonamallee High Road, Chennai-600077, Tamil Nadu, India Mail id: jessyp.sdc@saveetha.com

**Corresponding Author:Dr. SubhabrataMaiti, Senior Lecturer, Department of Prosthodontics, Saveetha Dental College, Saveetha Institute of Medical And Technical Sciences, Saveetha University, 162, Poonamallee High Road, Chennai-600077, Tamil Nadu, India, Phone no:9007862704, Mail id: subhabratamaiti.sdc@saveetha.com*

foundation is required for CD retention, stability, and support. Over the past decade, the emergence of new impression materials has contributed to the development of impression theories, resulting in better techniques being developed[3].

Proper impression procedures are integral for obtaining a peripheral seal for good retention and proper extensions for a full denture's support and stability. The final impression will be similar in thickness and length to the limits of the definitive complete denture prosthesis[4]. To ensure proper retention and stability of a complete denture, the follow-up steps are imperative an adequate preliminary impression, manufacture of a custom tray, border molding of the custom tray, and final impression of the edentulous arch, which should be a precise representation of the present anatomy[5]. Several materials are available for each of these procedures and have been recommended. The oral mucosa of completely edentulous patients is subject to various kinds of mechanical forces. The forces include the massaging effect of tongue and soft food, or unfavorable conditions, such as particles of relatively hard food. With the insertion of complete dentures, the forces acting on the mucosa are greatly changed. Both traumatic and massaging forces prevent direct tissue contact. Instead, the tissues are subjected to the rubbing effect of the moving denture and the denture base 's mechanical displacement of the tissues[6]. The technique used in the making of impressions plays an important role in the reaction of supporting tissues to complete dentures. Impressions are made with a minimum (mucostatic) pressure, maximum (biting) pressure, or functional pressure.[7].

Flabby tissues present the clinician with a challenging clinical scenario to ensure a well-fitting prosthesis, often called a fibrous ridge or displaceable ridge, Flabby ridge is mobile soft tissue present on the alveolar ridge's superficial part. Flabby ridge is prevalently seen in the upper anterior region and is commonly associated with combination syndrome characteristics. There is, however, a lack of agreement among dental practitioners on impression materials and techniques for CD denture[8]. Despite the large volume of literature on patient satisfaction with complete denture therapy, there is no consensus among authors regarding reliable predictors of success in a denture. If a definitive impression technique could be developed that was easier to perform than conventional border molding techniques with a compound for modeling plastic impression, took less clinical time and did not increase the number of post-insertion visits to dental offices, then more dentists could choose to treat more edentulous patients with complete dentures with direct digital impressions of edentulous impression[9]. Several reports have focused on the feasibility and accuracy of digital intraoral impressions for complete Dentures, but there is a paucity of literature on this aspect[10].

This article focuses on complete denture impression techniques used by Prosthodontics Postgraduates, Undergraduate, and Dental Practitioners.

II. MATERIALS AND METHODS :

A cross-sectional online survey was conducted after the validation done by 5 prosthodontic lecturers. The survey involved a sample size of 100 done, the survey form was sent to 150 Prosthodontists out of that 100 responses were received. 100 samples based on a random sampling method which included Prosthodontics postgraduates, Undergraduates, and General Practitioners from different locations in India with proper consent from the participants about the various impression techniques done for completely edentulous patients. The results were collected and then analyzed through SPSS software version 22. Descriptive statistical analysis was carried out and the chi-square test was used and the p-value was calculated.

III. RESULTS AND DISCUSSION:

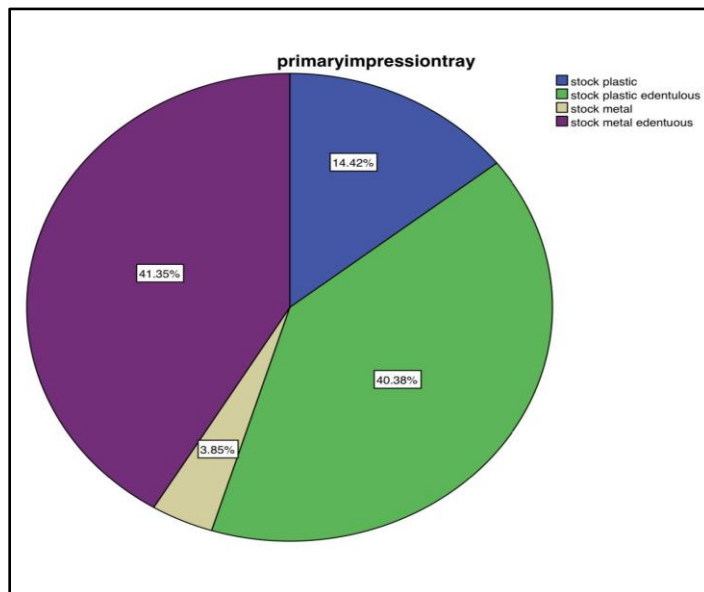


Figure 1 shows the preference of tray by the dental practitioners for taking a preliminary impression in which 14.42% of the dental practitioners use the stock plastic tray as the primary impression tray, 40.38% of the dentist use stock plastic edentulous tray which is shown to be the most used impression tray for primary impression, 3.85% of the dentist use stock metal tray and 41.35% of the dental practitioners use stock metal edentulous tray, which is shown to be the highly used impression tray by dentists .

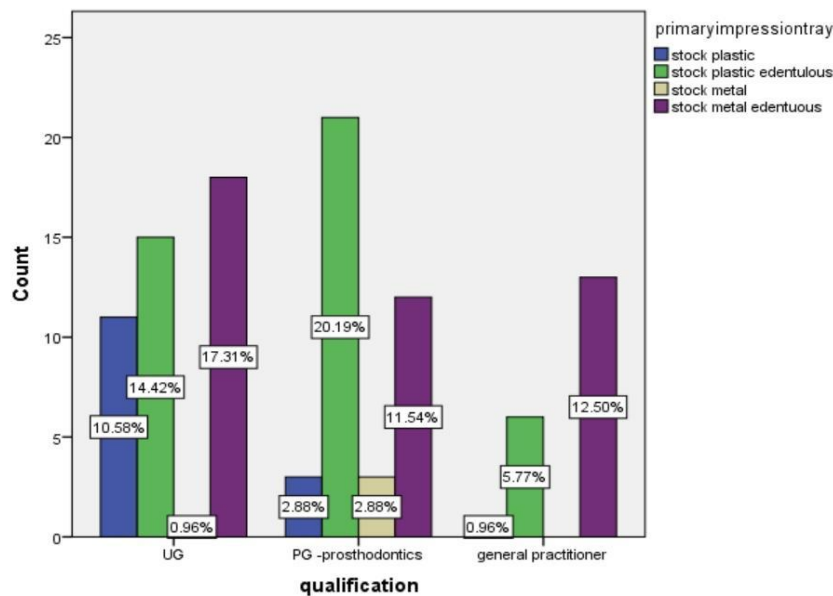


Figure 2 shows the bar chart representing the statistical correlation between the qualification of dentists on the use of the type of impression tray in completely edentulous patients (blue color represents stock plastic impression tray, green color represents stock plastic edentulous tray, brown color represents stock metal tray and purple color denotes stock metal edentulous tray) The X-axis denotes the qualification, preferring the tray used for taking a preliminary impression and Y-axis denotes the number of responses.

10.58% of UG prefer using stock plastic impression tray, 14.42% of UG preferred using stock plastic edentulous tray, 0.96% of UG prefer using stock metal impression tray and 17.31% of UG dental practitioners prefer using stock metal edentulous tray for taking primary impression. The preference of using primary impression tray among PG prosthodontists shows that 2.88% of PG prefer using stock plastic impression tray, 20.19% prefer using stock plastic edentulous tray, 2.88% prefer using a stock metal tray and 11.54% of PG prefer using stock metal edentulous tray. The results of use of primary impression among general practitioners showed that 0.96% of general practitioners use a stock metal tray, 5.77% prefer stock plastic edentulous tray, and 12.50% preferred stock metal edentulous tray for taking primary impressions. It shows that there is a significant increase in the use of stock plastic edentulous tray among the PG prosthodontists. p value <0.05 (p value=0.02) which is statistically significant.

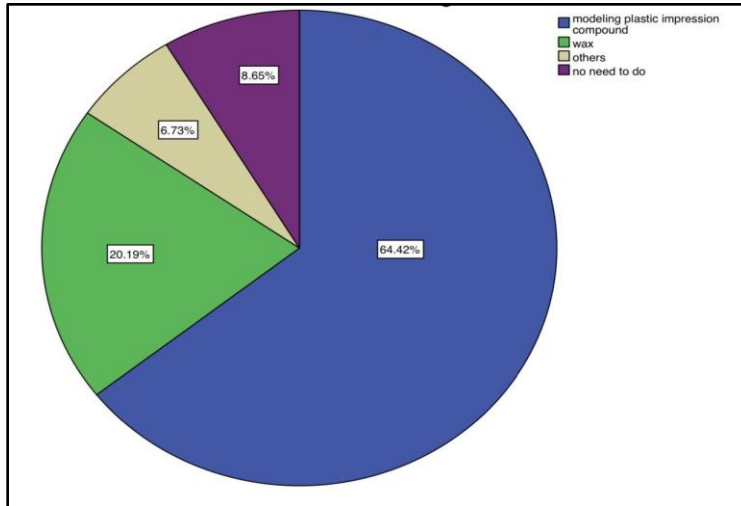


Figure 3 shows the impression material used for the border molding of preliminary impression, which shows the 8.65% of the dentist prefer no border molding, 6.73% of the dentist prefer using other materials like silicone-based material, 20.19% of the dental practitioners use wax for the border molding of primary impression and 64.42% of dentist use modeling plastic impression compound for the border molding of a primary impression which is shown to be the most used and preferred border molding impression material when compared to the other materials.

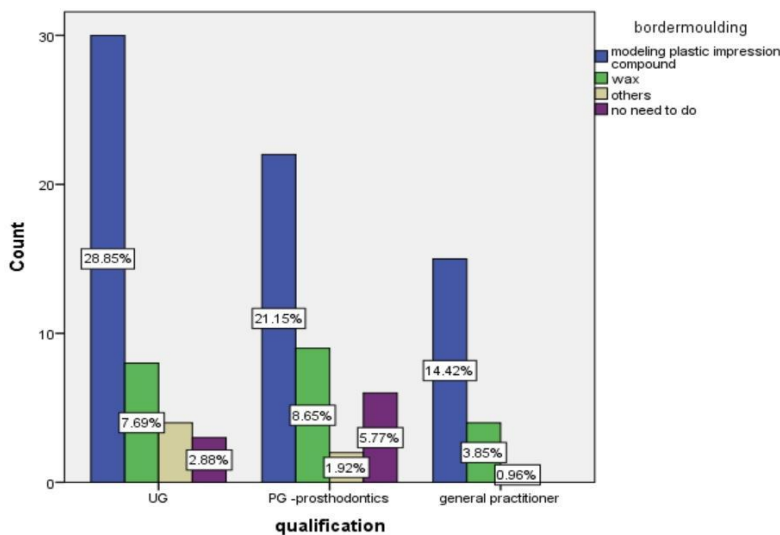


Figure 4 shows the statistical correlation between the qualification of dentists and the material used for the border molding of primary impression for completely edentulous patients in which Blue color represents modeling plastic impression compound, green color represents wax, brown color represents others and purple color represents no need of border molding.

The X-axis denotes the qualification, preferring the material used for the border molding of primary impression for completely edentulous patients and the Y-axis represents the number of responses. The preference of material used for border molding among UG dental practitioners are 28.85% prefer modeling plastic impression compounds, 7.69% prefer wax, 2.88% of usually prefer no border molding. The preference of material used for border molding among PG prosthodontists shows that 21.15% prefer modeling plastic impression compounds, 8.65% prefer wax, 1.92% prefer other materials, 5.77% of dentists prefer no border molding. The preference of material for border molding among general practitioners is 14.42% prefer modeling plastic impression compounds, 3.85% of general practitioners prefer using wax and 0.96% prefer other materials for border molding.

It shows that there is no significant difference between the qualification and impression material used for border molding.

p value >0.05 (p value=0.4) which is statistically insignificant.

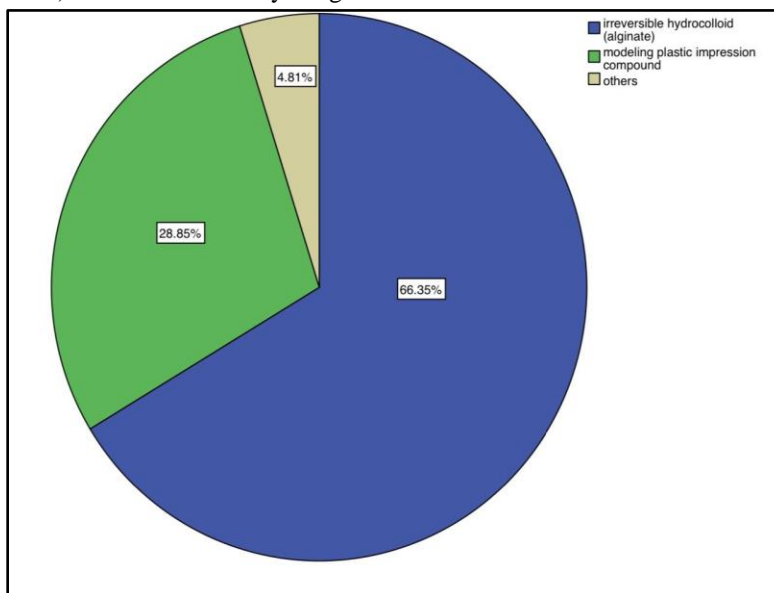


Figure 5 shows the impression material preferred by dental practitioners for taking a preliminary impression for completely edentulous patients, which shows 66.35% of dental practitioners use irreversible hydrocolloid (alginate) which is the most used primary impression material, 28.85% dental practitioners use modeling plastic impression compound and 4.81% of the dental practitioners prefer the use of other impression materials other than the given options, most probably silicone rubber base putty. The rest didn't reply.

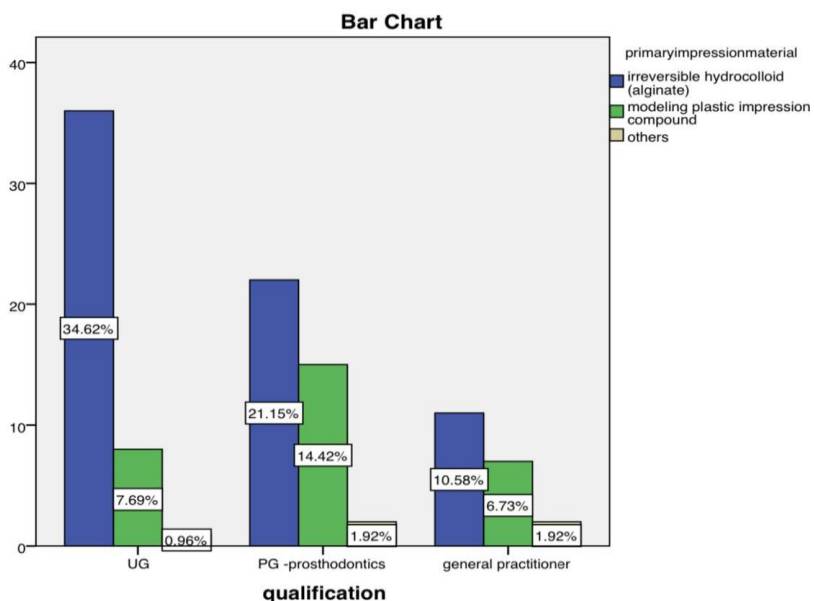


Figure 6 shows a statistical correlation between the qualification of dentists on the materials used for taking the primary impression for completely edentulous in which blue color represents irreversible hydrocolloid, green color represents modeling plastic impression compound and brown color represents other impression materials. The X-axis represents the qualification, preferring the materials used for taking the primary impression and the Y-axis denotes the number of responses.

The use of primary impression material among UG dental practitioners is that 34.62% prefer using alginate, 7.69% prefer using plastic impression compounds and 0.96% prefer using other impression materials. The preference of using impression material for taking primary impression among PG prosthodontists is that 21.15% prefer using alginate, 14.42% prefer using plastic impression compounds and 1.92% prefer using other impression materials.

It shows that there is a significant increase in use of alginate among UG dental practitioners for taking primary impressions.

p value < 0.05 (p value = 0.09) which is statistically significant.

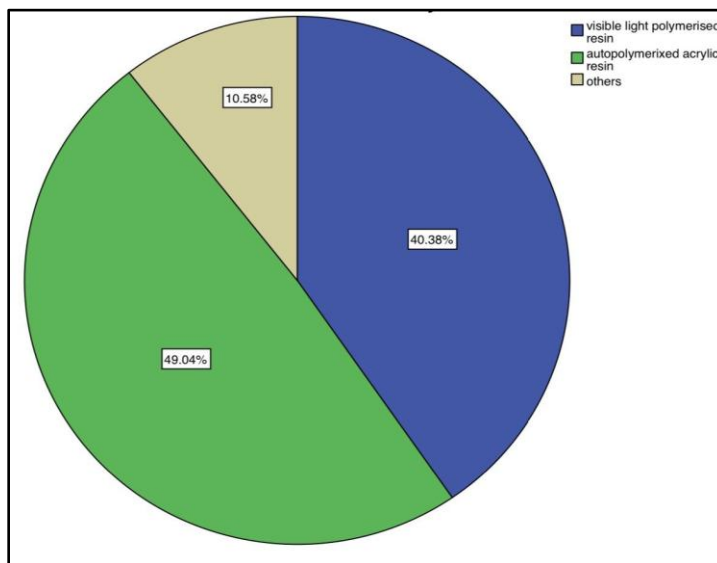


Figure 7 shows the preference of custom tray in case of taking a preliminary impression, which shows that 40.38% of the dental practitioners use light polymerized resin as a custom tray for fabricating primary impression, 49.04% of the dental practitioners use auto polymerized acrylic resin as a custom tray for fabricating primary impression, which

is shown to be the most preferred by the dental practitioners and 10.58% of dental practitioners use other materials like shellac base for the fabrication of custom tray for preliminary impressions.

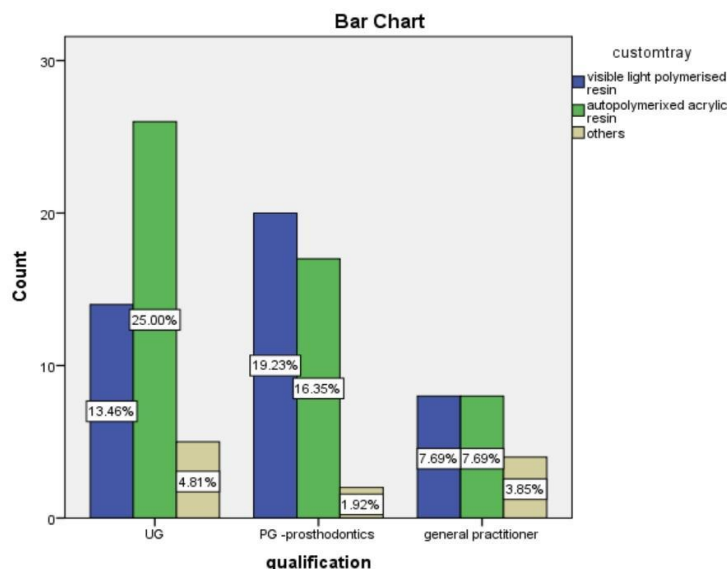


Figure 8 shows a statistical comparison between the qualification of dentists on the custom tray used for primary impression for taking a preliminary impression for completely edentulous patients was done in which blue color denotes visible light polymerized resin, green color denotes auto polymerized acrylic resin and brown denotes other materials. The X-axis denotes the qualification, preferring the use of custom tray used for taking primary impressions for completely edentulous patients and the Y-axis denotes the number of responses.

The use of material for the fabrication of custom tray among UG is that 13.46% of usually prefer using visible light polymerized resin, 25% preferred using auto polarised acrylic resin, 4.81% preferred using other materials. The use of material for fabrication of custom tray among PG prosthodontists is that 19.23% prefer using visible light polymerized resin, 16.35% prefer using auto polymerized acrylic resin and 1.92% prefer using other materials. The use of material for fabrication of custom trays among general practitioners is that 7.69% preferred using visible light polarisation, 7.69% before using auto polymerized acrylic resin, and 3.85% preferred using other materials for the fabrication of custom trays.

It shows that there is no significant difference between the qualification and use of material for the fabrication of custom trays.

p value >0.05 (p value=0.1) which is statistically insignificant.

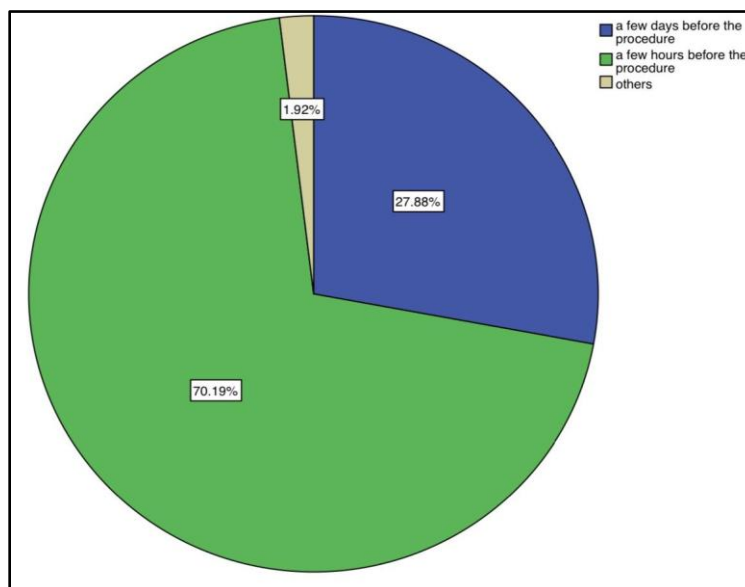


Figure 9 shows methods followed by the dental practitioners to prevent distortion of custom trays, which shows that 27.88% of dental practitioners prefer fabricating custom tray a few days before the procedure to prevent distortion, 70.19% of dental practitioners prefer fabrication of custom tray a few hours before (6 hours at least) the procedure which is to be the ideally preferred method according to previous studies and clinical trials (the most preferred according to the survey) and 1.92% of the dental practitioners use other methods like immediate fabrication for fabrications of the custom tray for impression making.

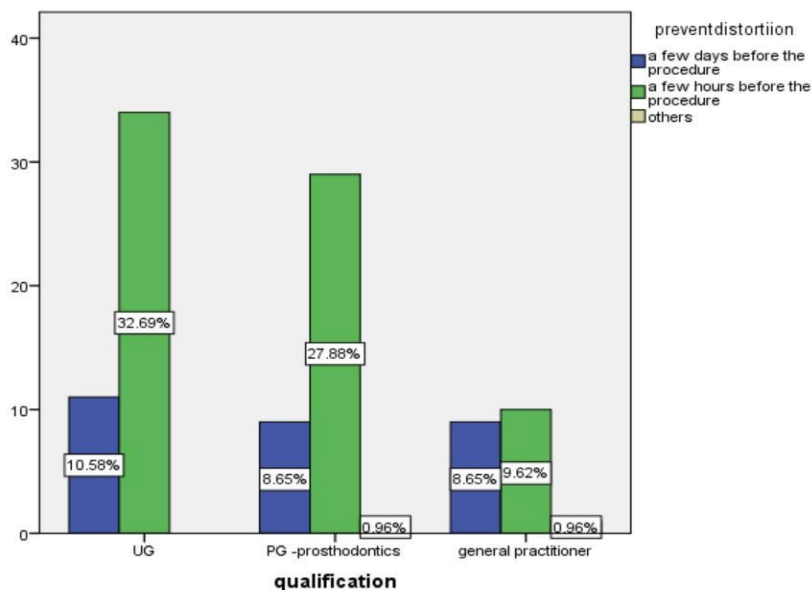


Figure 10 shows the statistical correlation between the qualification of dentists and the methods followed to prevent distortion of custom trays for completely edentulous patients in which blue color denotes a few days before the procedure, green color denotes a few hours before the procedure and brown color denotes other methods. The X-axis represents the qualification, preferring the methods followed to prevent distortion of custom trays in completely edentulous patients and the Y-axis denotes the number of responses.

The method followed by UG dental practitioners to prevent distortion during custom tray fabrication is that 10.58% preferred fabricating custom tray a few days before the procedure, 32.69% preferred fabricating customary a few hours before the procedure. The method used to prevent distortion during custom tray fabrication among PG

prosthodontists is that 8.65% prefer supplicating custom tray a few days before the procedure, 27.88% of PG prefer fabricating custom tray a few hours before the procedure and 0.96% prefer other methods. The method followed by general practitioners to prevent distortion during custom tray is that 8.65% preferred fabricating custom tray a few days before the procedure, 9.62% preferred fabricating custom tray a few hours before the procedure and 0.96% preferred other methods.

It shows that there is no significant difference between qualification and methods used to prevent distortion during fabrication of custom trays.

p value >0.05 (p value=0.2)which is statistically insignificant.

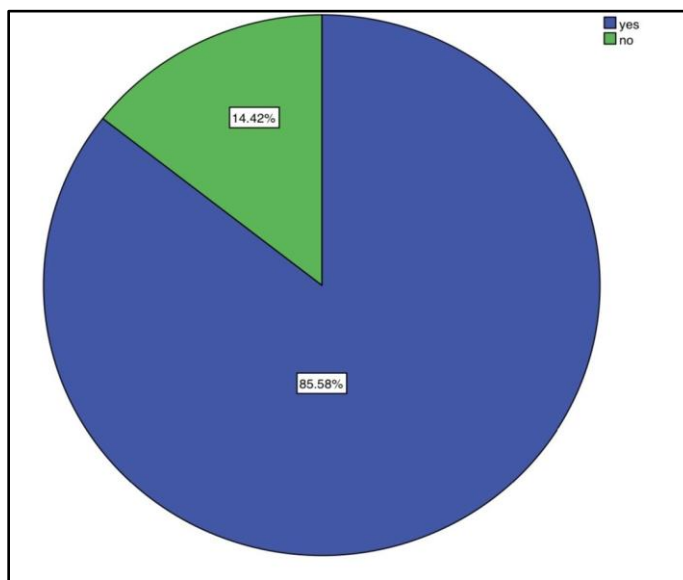


Figure 11 shows the preference by dental practitioners in using a spacer and tissue stop in the fabrication of custom tray, which shows that 85.58% of dental practitioners use space during custom tray fabrication and 14.42% of dental practitioners do not prefer the use of space or in the fabrication of custom tray.

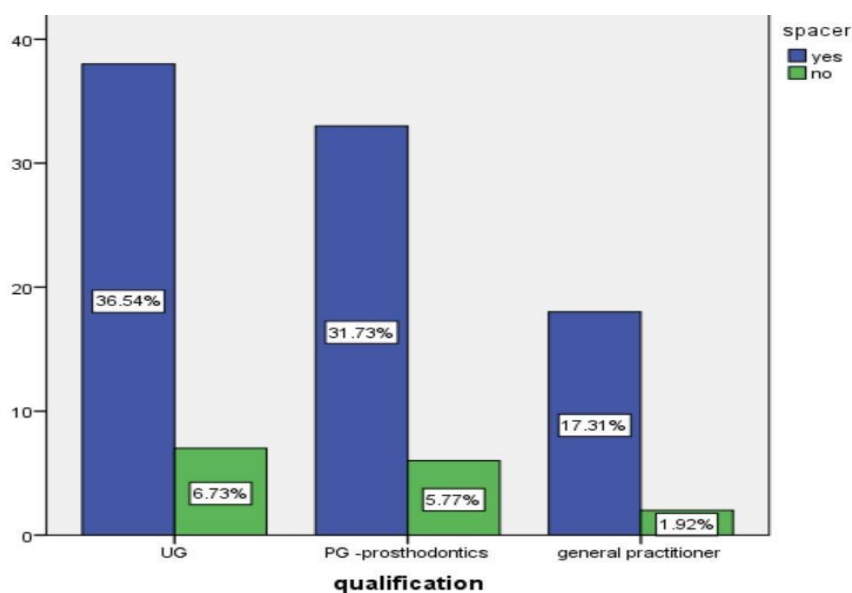


Figure 12 shows the statistical correlation between the qualification of dentists and the preference of using spacer and tissue stop in the fabrication of custom trays for completely edentulous patients in which blue color represents yes and green color represents no.

The X-axis represents the qualification, preferring the use of spacer and tissue stop in the fabrication of custom tray and Y-axis denotes the number of responses.

The preference of using spacers among UG dental practitioners is that 36.54% of UG preferred to use a spacer and 6.73% of UG don't prefer the use of spacers. The use of spacer among PG prosthodontists is that 31.73% prefer using spacer and 5.77% do not prefer using a spacer.

It shows that there is no significant difference between the qualification and use of spacer.

p value >0.05 (p value=0.8) which is statistically insignificant.

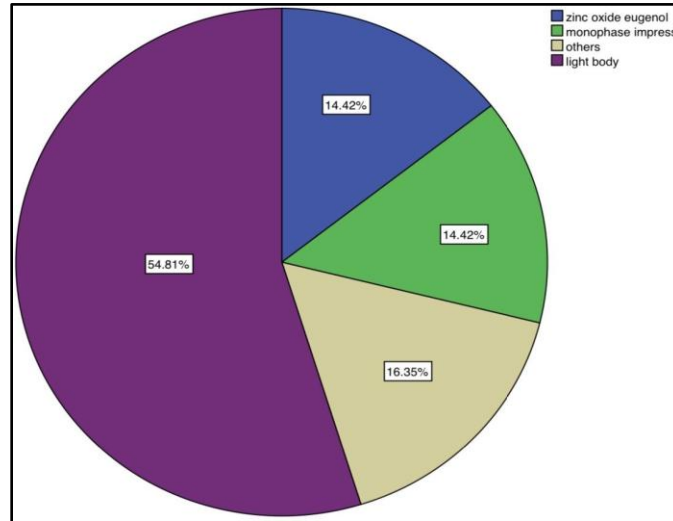


Figure 13 shows preference of dentist in the material used for taking a final impression for completely edentulous patients, which shows that 14.42% of the dental practitioners use zinc oxide eugenol as a final impression material, 14.42% of dental practitioners use Monophasic impression, 16.35% of dentist use other impression materials and 54.81% of the dental practitioners use the light body as the final impression material which is shown to be the most highly preferred final impression material .

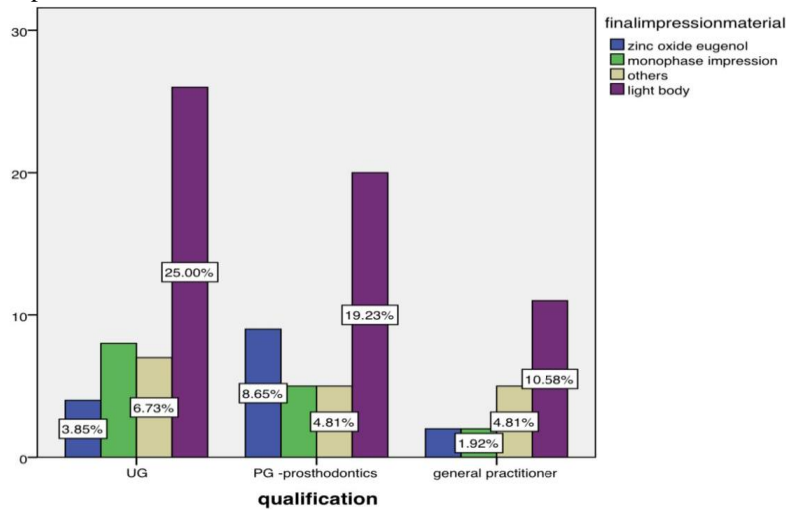


Figure 14 shows a statistical correlation between the qualification of dentists and the materials used for taking final impressions for completely edentulous patients in which blue color denotes zinc oxide eugenol, green color denotes monophasic impression material, brown color denotes other impression materials and purple color denotes light body. The X-axis represents the qualification, preferring the materials used for taking final impressions in completely edentulous patients and the Y-axis denotes the number of responses.

The preference of final impression material among UG is that 3.85% prefer using zinc oxide eugenol, 6.73% prefer using monophasic impression, 25% preferred using light body. The use of final impression material among PG prosthodontists is that 8.65% prefer using zinc oxide eugenol, 4.81% prefer using other materials and 19.23% prefer

using a light body. The use of final impression material among general practitioners is that 1.92% prefer using a monophasic impression, 4.81% prefer other materials and 10.58% preferred using the light body for taking a final impression in completely edentulous patients

It shows that there is no significant difference between qualification and use of final impression material for completely edentulous patients.

p value >0.05 (p value=0.5) which is statistically insignificant.

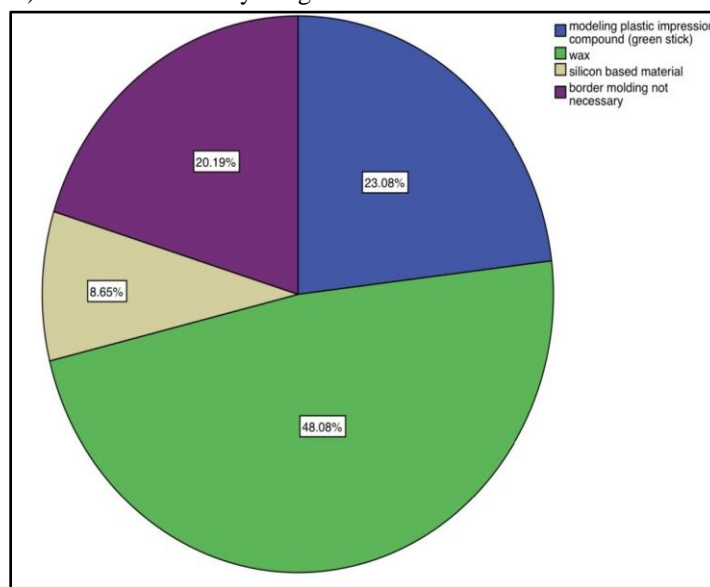


Figure 15 shows the preference of use of impression material for the border molding of final impression, which shows 23.08% of the dental practitioners use modeling plastic impression compound (greenstick compound) for the fabrication of final impression, 8.65% of dentists use silicon-based materials for final impression border molding, 48.08% practitioners use wax and 20.19% dental practitioners prefer no border molding of final impressions.

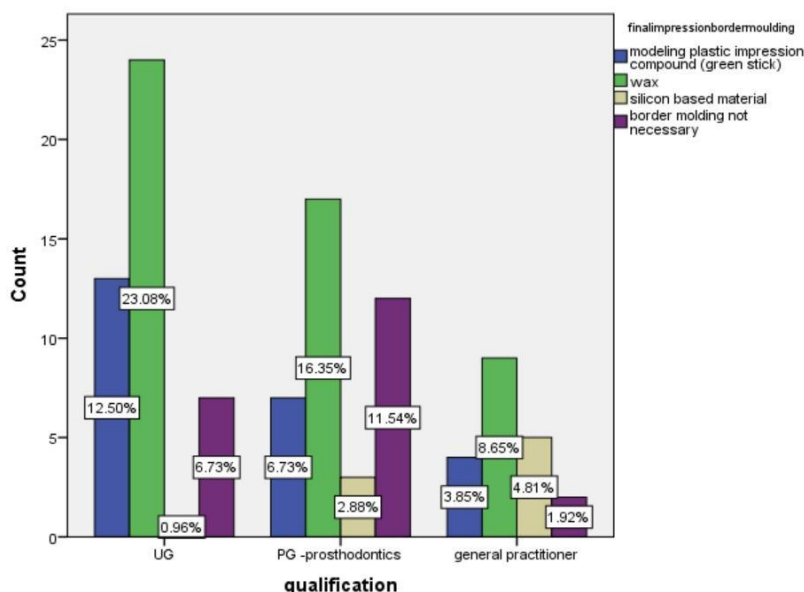


Figure 16 shows the statistical correlation between the qualification of dentists and the materials used for the border molding of the final impression for completely edentulous patients in which blue color denotes modeling plastic impression compound, green color denotes wax, brown color denotes silicon-based material and purple color denotes border molding not necessary.

The X-axis represents the qualification, preferring the materials used for the border molding of the final impression and the Y-axis denotes the number of responses.

The use of impression material for final impression board and molding among UG dental practitioners is that 12.50% prefer using modeling plastic impression compound, 23.08% prefer using wax, 0.96% prefer using silicon-based material, 6.73% prefer no border molding. The use of impression material for final impression border molding among PG prosthodontists is that 6.73% prefer using modeling plastic impression compound, 16.35% prefer using backs, 2.88% before using silicon-based material, 11.54% prefer no border molding. The use of impression material for border molding of a final impression among general practitioners is that 3.85% prefer using modeling plastic impression compound, 8.65% prefer using wax, 4.81% prefer using silicon-based material, 1.92% prefer no border molding at all.

It shows that there is a significant increase in the use of impression material used for the border molding of final impression among UG dental practitioners (wax).

p value <0.05 (p value=0.03)which is statistically significant.

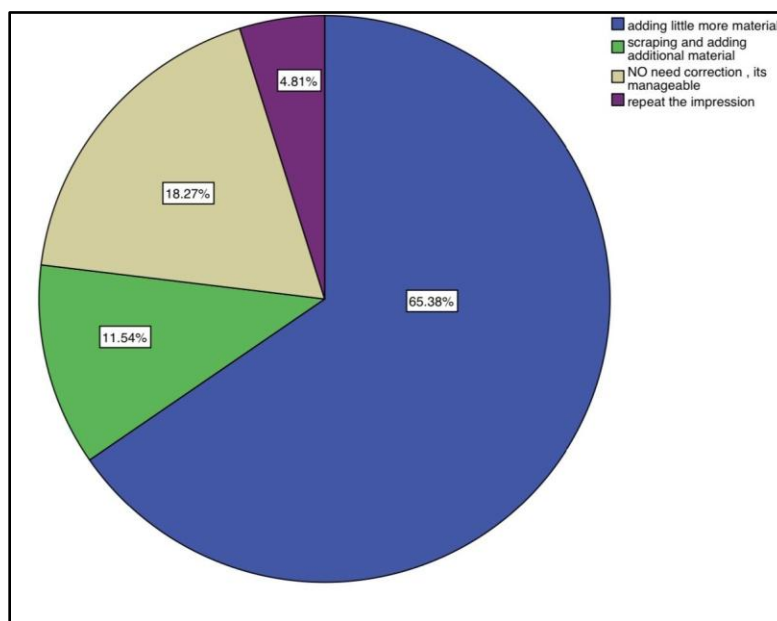


Figure 17 shows the method followed by the dental practitioners for the correction of a final impression which shows that 65.38% of the dentist follows adding little more impression material, 11.54% of dentists follow scraping and adding additional material, 18.27% dentist says no need of final impression correction since it is manageable and 4.81% of the dental practitioners prefer repeating the impression for correcting final impression.

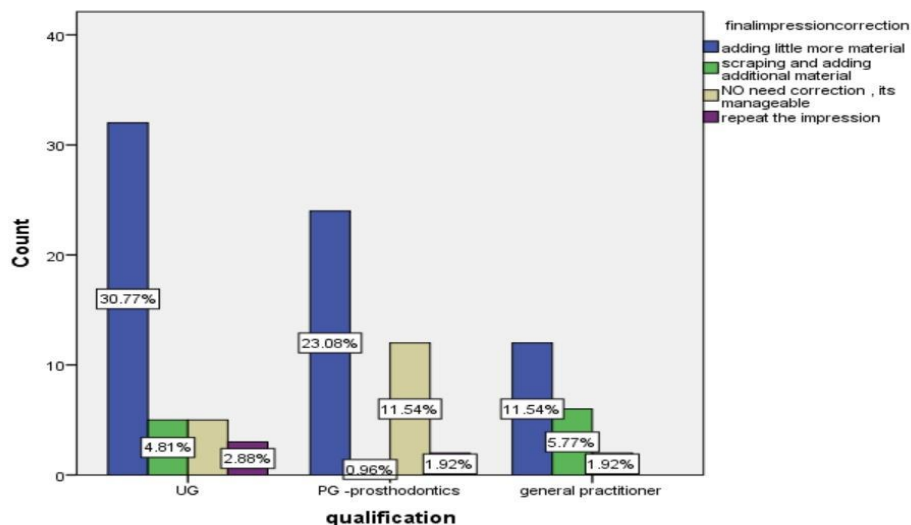


Figure 18 shows the statistical correlation between the qualification of dentists and the methods used for correction of final impression for completely edentulous patients in which blue color denotes adding little more material, green color denotes scraping and adding additional material, brown color denotes no need of correction and it's manageable, purple color denotes repeating the impression. The X-axis denotes the qualification, preferring the methods used for correction of final impression, and Y-axis denotes the number of responses.

The method used for final impression correction among UG dental practitioners is that 30.77% prefer the method of adding little more material, 4.81% prefer scraping and adding of additional material and 2.88% prefer repeating the impression. The method used for correcting the final impression among PG Prosthodontists is that 23.08% prefer adding little more material, 0.96% prefer scraping and adding additional material, 11.54% prefer no correction and 1.92% prefer repeating the impression. The method used for correction of a final impression among general practitioners is that 11.54% prefer adding little more material, 5.77% prefer scraping and adding additional material and 1.92% prefer repeating the impression.

It shows that there is a significant increase in the qualification and the use of method(adding little more material) for the correction of final impressions among UG dental practitioners.

p value >0.05 (p value=0.01)which is statistically significant.

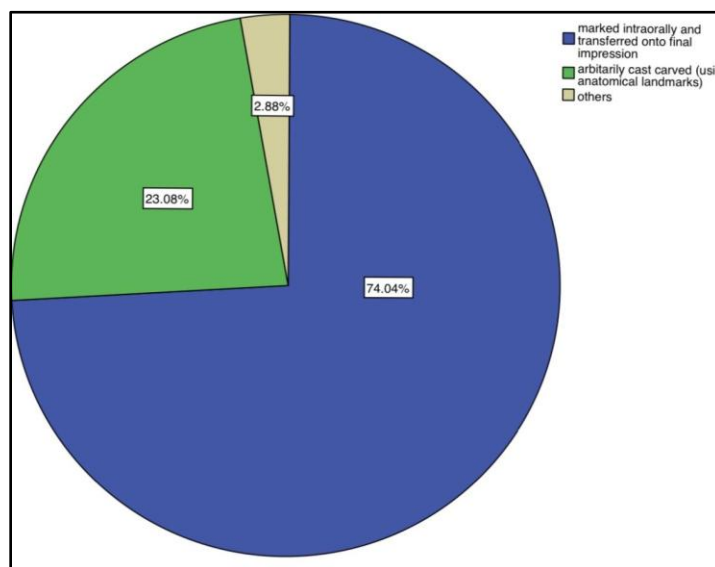


Figure 19 shows the method used for locating the posterior border in which, 74.04% of the dental practitioners follow marking intraorally and transfer into final impressions, 23.08% dentist prefer following arbitrary caste carved

using anatomical landmarks for locating posterior border and 2.88% of dental practitioners follow methods other than the given two options for locating posterior borders during impression taking.

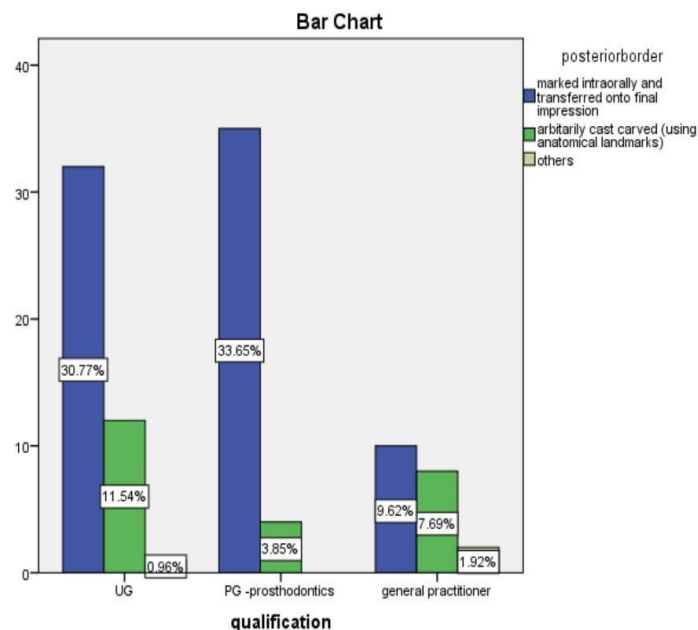


Figure 20 shows a statistical correlation between the qualification of dentists and the methods used for locating the posterior border edentulous patients in which blue color denotes marked intraorally and transferred onto final impression, green color denotes arbitrarily caste carved and brown color denotes other methods for locating the posterior border. The X-axis represents the qualification, preferring the methods used for locating the posterior border for completely edentulous patients and the Y-axis denotes the number of responses.

The methods followed by UG dental practitioners for locating posterior border is that 30.77% follow marked intraorally and transferred onto final impression, 11.54% followed arbitrarily caste carved and 0.69% preferred other methods for locating posterior border. The method followed by PG prosthodontists for locating posterior border is that 33.65% followed marked intraorally and transferred onto final impression and 3.85% followed arbitrarily caste carved. The method followed by general practitioners for locating the posterior border is that 9.62% followed mark intraorally and transferred onto final impression, 7.69% preferred arbitrarily caste carved and 1.92% preferred other methods for the location of posterior border.

It shows that there is a significant increase in the methods used by PG prosthodontists for locating the posterior border (marked intraorally and transferred onto final impression).

p value <0.05 (p value=0.01) which is statistically significant.

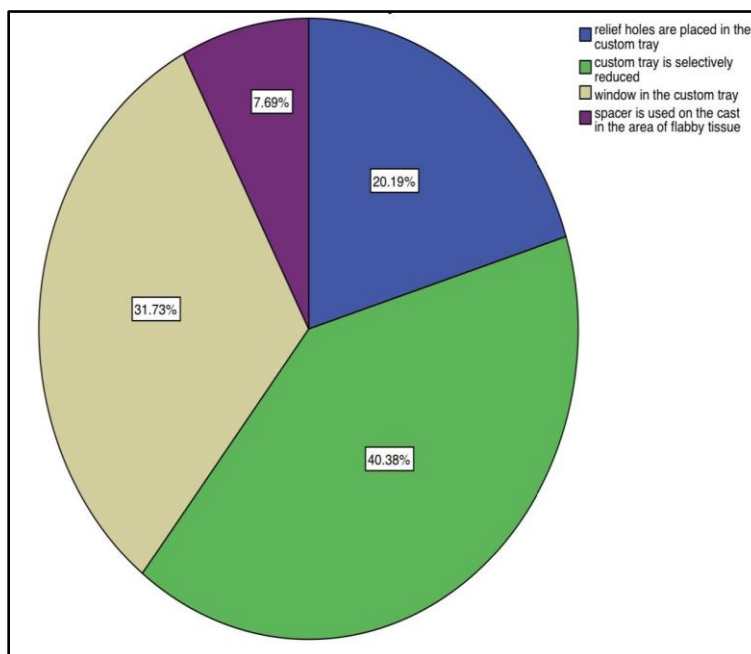


Figure 21 shows the steps followed by dental practitioners in case of incidence of a condition called flabby tissue, which shows that 20.19% of dentists prefer placing relief holes in the custom tray, 40.38% dentists follow the method of selectively reducing the custom tray and 31.73% of dental practitioners prefer placing a window in the custom tray in case of flabby tissue conditions.

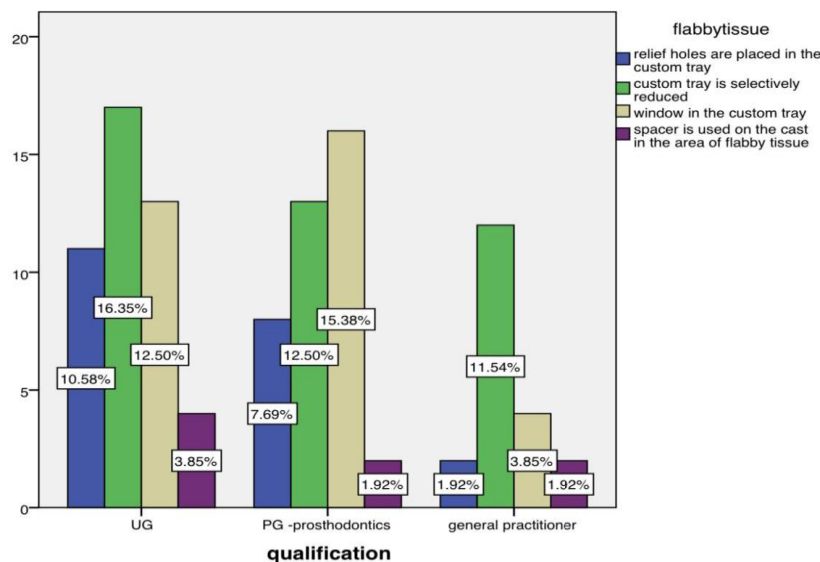


Figure 22 shows a statistical correlation between the qualification of dentists and the methods followed for the management of flabby tissue for completely edentulous patients in which blue color denotes relief holes are placed in the custom tray, green color denotes custom tray is selectively reduced, brown color denotes window in the custom tray and purple color denotes the spacer is used on the cast in the area of flabby tissue. The X-axis denotes the qualification, preferring the methods followed for the management of flabby tissue and the Y-axis denotes the number of responses.

The method used for the management of flabby tissue among UG dental practitioners is that 10.58% preferred placing relief holes in the custom tray, 16.35% prefer selectively reducing the custom tray, 12.50% prefer placing a window in the custom tray and 3.85% prefer using spacer on the cast in the area of flabby tissue. The methods used

for the management of flabby tissue among PG prosthodontist is that 7.69% before placing relief holes in the custom tray, 12.50% prefer selectively reducing the custom tray, 15.38% prefer placing window in the custom tray and 1.92% prefer using spacer on the tray in the area of flabby tissue. The method used for the management of flabby tissue among general practitioners is that 1.92% prefer placing relief holes in the custom tray, 11.54% prefer selectively reducing the custom tray, 3.85% before placing a window in the custom tray and 1.92% prefer using a spacer on the cast in the area flabby tissue.

It shows that there is no significant difference between qualification and the methods used for the management of flabby tissue.

p value >0.05 (p value=0.4)which is statistically insignificant.

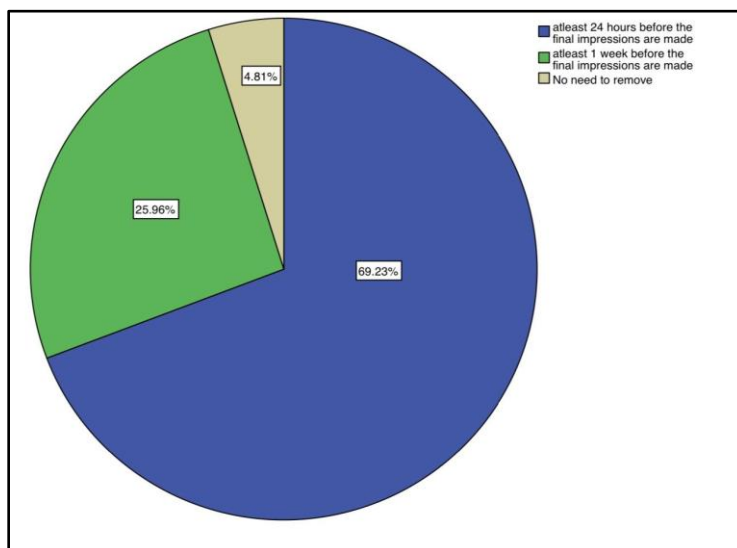


Figure 23 shows the removal of existing denture of the patient during final impression taking, which shows, 69.23% of the dental practitioners suggest removing the existing denture of the patient, at least 24 hours before the final impressions are made, 25.96% of the dental practitioners suggest bearing the existing dentures at least one week before the final impressions are made and 4.81% of dental practitioners prefer not removing the existing dentures.

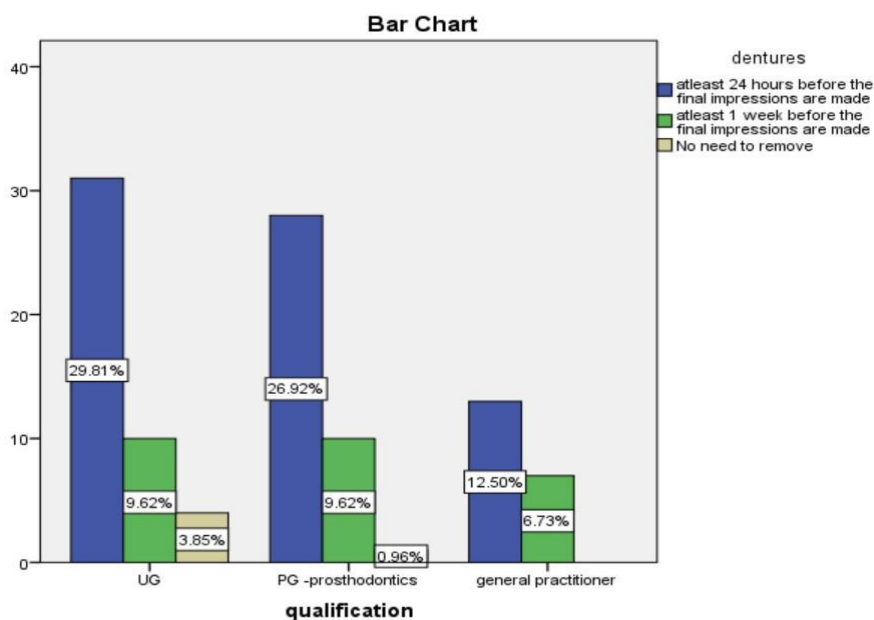


Figure 24 shows a statistical correlation between the qualification of dentists and the use of existing dentures of the patient during impression taking for completely edentulous patients in which blue color denotes the removal of

existing denture at least 24 hours before the final impressions are made, green color denotes at least one week before the final impressions are made and brown color denotes no need for the removal of existing dentures. The X-axis represents the qualification, preferring the removal of existing dentures of the patient during impression taking and the Y-axis denotes the count of procedures.

The preference of removal of existing denture before final impression taking among UG dental practitioners is that 29.81% prefer removing existing denture at least 24 hours before the final impressions are made, 9.62% prefer removing existing denture at least one week before the final impressions are made and 3.85% prefer not removing the existing dentures. The preference of removal of existing denture among PG prosthodontists is that 26.92% prefer removing the existing denture at least 24 hours before the final impressions are made, 9.62% prefer removing dentures at least one week before the final impressions are made and 0.96% prefer no need of removing existing dentures. The preference of removing existing dentures among general practitioners is that 12.50% prefer at least 24 hours before final impressions are made and 6.73% prefer removing existing dentures at least one week before the final impressions are made.

It shows that there is no significant difference between the qualification and the removal of existing dentures during final impression taking.

p value >0.05 (p value=0.4) which is statistically insignificant.

A strategy for satisfying the impression can be suggested. A primary impression may be done in a combination of an alginate or an impression compound[11]. A final impression may be recorded in ZOE(zinc oxide eugenol) paste, non-eugenol paste, or light body elastomer in a tray material or cold cure or light cure custom tray with border molding in low fusing compound and final impression. This should give a reasonably accurate impression to prepare complete dentures well designed[12]. Elastomer usage to perform border molding takes less time and it's easy. The use of alginate in a custom tray can not be justified by using putty and wash in stock or plastic tray without having a secondary imprint[13].

Most of the Prosthodontists involved in this survey used preliminary impression material permanent hydrocolloid, which is the most commonly used. Previous surveys also found permanent hydrocolloid as the material of choice for early impressions (figure3)[14]. The other studies showed that most prosthodontists used preliminary impressions with wax for the border molding technique. Instead of modeling plastic impression compounds, some of the advantages of using wax for border molding include ease of handling, ease of trimming, and ease of casting from impression[15]. The disadvantages of using wax include possible wax distortion or displacement during insertion and mouth removal of the tray. Also, insufficient wax bulk at the edges of the tray could risk breaking the preliminary cast, especially when deep undercuts are present[16]. Previous surveys conducted earlier showed that most Prosthodontists used a light-curing resin material to make the custom tray. Based on the current survey, auto polymerized acrylic resin and a cold cure were the material of choice for custom tray fabrication[17] may be because the cost of the material is low. On the other hand, the benefits of light-curing material are high strength and stiffness, ease of handling, and complete polymerization without residual monomer, so another set of prosthodontists preferred the material (figure 4). There was a variation between programs in terms of the method used for border molding the custom trays as well as in the choice of border molding material[18]. Previous surveys showed that plastic compounds were the most popular material used to mold the custom tray border. A significant benefit of using elastomeric impression materials for border molding is the ability to record all borders at the same time. This in turn is less time consuming than sectional border molding and also minimizes the probability of border molding errors in one section[19]. In this study, we got PVS (Polyvinyl siloxane)silicon material that is most preferable followed by a plastic green stick compound. 20% Prosthodontists don't believe in border molding because they are following simplified denture concepts where there is no evidence of border molding. Many surveys report that the materials used for the final impressions vary. PVS, polysulphide, and polyether were among the widely used print materials for the final impressions. The results of this survey indicate significant differences between the currently used materials and those recorded in previous surveys. The current findings showed that the light body impression material is becoming more common[20]. Some of the benefits of using a light body material are ease of handling and storage, dimensional stability, sufficient working and setting times and enhancement of these materials' properties (figure 7)[21]. These results were consistent with the finding that most of the dentists spaced up their custom trays, most of

them used vent holes in the custom tray, and some of them incorporated tissue stops into their custom trays. Different studies have reported the importance of controlling the pressure while making an impression. Based on the responses, for excessive mobile tissue (flabby tissue), the majority of prosthodontist made special consideration of using a custom tray with a selective reduction and window over the flabby tissues, the most widely used method for flabby tissue management involves creating an impression with zinc oxide eugenol paste[22]. Any impression material is then removed in the window area, and impression plaster is added to complete the impression over the flabby tissues. In this study, a custom tray is selectively reduced in the case of flabby tissue followed by window technique was preferred (figure 11)[23]. With respect to the posterior palatal seal, this survey and other studies intraorally marked the posterior palatal seal area and then transferred it to the final impression. Most prosthodontists used a ball burnisher to intraorally palpate the depth of the displaceable tissue[24]. There are different ways, according to the literature, to locate and move the posterior palatal seal (figure 10)[25]. Most Prosthodontists routinely advised their patients not to wear their existing dentures for at least 24 hours before the final impressions were made[26]. The results of this survey reveal the current trends in taking impressions for completely edentulous patients and provide a clear view of the techniques and materials used in fabricating complete denture prosthesis (figure 12)[27].

While this survey showed inconsistencies in complete denture impression procedures and the selection of available impression materials among Indian prosthodontists, the results showed interesting trends following : 1. The majority of respondents used irreversible hydrocolloids for preliminary impressions in a stock metal edentulous tray similar to previous literature[28], 2. The overwhelming majority of prosthodontists conducted border molding in custom acrylic resin auto polymerizing trays and also a light-curing special tray with no significant differences and silicon material is preferred border molding material followed by green stick compound showing the advancement of practice, 3. Selective pressure technique was the largest used impression technique among the majority of respondents which was in accordance with previous literature (Shannon[29], 4. The light body was the material of choice for the final impression the same as the study done before[30].

The limitations include, fewer samples can be done on a large scale.

IV. FUTURE PERSPECTIVE :

Analysis of the knowledge and awareness of impression techniques followed by dental practitioners provides a clear view to the all the dentists about the various techniques of impression taking followed in today's dentistry which helps in reducing the errors caused during impression taking and it also provides the public a view about the necessity, methods, uses, advantages, and disadvantages of impression making to provide betterment in techniques of impression taking for completely edentulous patients in the future[31].

V. CONCLUSION :

This survey highlights the knowledge and practice of impression techniques followed by Indian dental practitioners for completely edentulous patients, which has provided a clear view about the current procedures undertaken by the dentists and also provides a baseline data with exposing of lacunae wherein further research can be done to improve certain procedures and techniques for the betterment of patients in the future.

QUESTIONNAIRE USED FOR THE STUDY:

- Name
- Age
- What type of tray is used for making a preliminary impression? *

Stock plastic

Stock plastic edentulous

Stock metal edentulous

Stock metal

- What material is used for border molding the preliminary impression? *

Modeling plastic impression compound

Wax

Others

no need to do

- What material is used for making a preliminary impression?

Irreversible hydrocolloid (alginate)

Modeling plastic impression compound

Others

- Which impression theory/philosophy is predominantly used in your practice?

Mucostatic

Selective pressure

Functional

Dynamic impression technique

Others

- What material is used for the fabrication of a custom tray?

Visible light polymerized resin

Autopolymerizing acrylic resin

Heat processed acrylic resin

Others

- When is the custom tray fabricated (to prevent distortion)?

A few days before the procedure

A few hours before the procedure

Others

- Is the spacer used in the fabrication of a custom impression tray?

Yes

No

- Are tissue stops placed in the custom impression tray?

Yes

No

- What material is used for making a final impression?

Zinc oxide eugenol

Monophase impression

Alginate

Light body

Others

- Correction of final impression can be done by

Adding little more material

Scraping and adding additional material

No need correction, it's manageable

Repeat the impression

- What material is used for border molding of final impressions?

Modeling plastic impression compound (green stick)

Wax

silicon-based material

border molding not necessary

- How is relief placed in the impression of excessive flabby tissue?

Relief holes are placed in the custom tray

The custom tray is selectively reduced

Window in the custom tray

The spacer is used on the cast in the area of the flabby tissue

- The technique for locating the posterior border *

Marked intra-orally and transferred onto the final impression

Arbitrarily cast carved (using anatomic landmarks)

Others

Other:

- Patients routinely advised to not wear their existing dentures for *

At Least 24 hours before the final impressions are made

At Least 1 week before the final impressions are made

No need to remove

Other:

- Have you done digital intraoral impression techniques for edentulous patients?

Yes

No

- Absence of neutral zone leads to

Stability

Discomfort the patient

All of the above

None of the above

Others

REFERENCE :

- [1] Ariga P, Nallaswamy D, Jain AR, Ganapathy DM. Determination of Correlation of Width of Maxillary Anterior Teeth using Extraoral and Intraoral Factors in Indian Population: A Systematic Review. *World Journal of Dentistry* 2018;9:68–75.
- [2] Albuquerque IS, Freitas-Pontes KM, de Souza RF, Negreiros WA, Ramos MB, Peixoto RF, et al. Is a two-step impression mandatory for complete denture fabrication on the severely resorbed mandible? A randomized trial on mastication, patient satisfaction and adjustments. *J Dent* 2020:103357.
- [3] Cupero HM. Impression technique for complete maxillary immediate denture. *The Journal of Prosthetic Dentistry* 1978;39:108–9. [https://doi.org/10.1016/s0022-3913\(78\)80057-2](https://doi.org/10.1016/s0022-3913(78)80057-2).
- [4] Albuquerque IS, Regis RR, de Souza RF, Gurgel KF, Silva PGB, Pinto-Fiamengui LMS, et al. Is a two-step impression mandatory for complete denture fabrication on the severely resorbed mandible? A randomized trial on patient perception and denture quality. *Journal of Dentistry* 2020;98:103356. <https://doi.org/10.1016/j.jdent.2020.103356>.
- [5] Jyothi S, Robin PK, Ganapathy D, Anandiselvaraj. Periodontal Health Status of Three Different Groups Wearing Temporary Partial Denture. *Research Journal of Pharmacy and Technology* 2017;10:4339. <https://doi.org/10.5958/0974-360x.2017.00795.8>.
- [6] Alqattan WA, Alalawi HA. Impression Techniques and Materials for Complete Denture Construction. *Dental Health: Current Research* 2016;2. <https://doi.org/10.4172/2470-0886.1000113>.
- [7] Duraisamy R, Krishnan CS, Ramasubramanian H, Sampathkumar J, Mariappan S, NavarasampattiSivaprakasam A. Compatibility of Nonoriginal Abutments With Implants: Evaluation of Microgap at the Implant-Abutment Interface, With Original and Nonoriginal Abutments. *Implant Dent* 2019;28:289–95.
- [8] de Resende GP, Nogueira TE, Leles CR. Effectiveness of a simplified method for final impression in complete denture treatment: A pragmatic clinical trial. *Gerodontology* 2019;36:365–73.
- [9] Petropoulos VC, Rashedi B. Current concepts and techniques in complete denture final impression procedures. *Journal of Prosthodontics* 2003;12:280–7. [https://doi.org/10.1016/s1059-941x\(03\)00108-6](https://doi.org/10.1016/s1059-941x(03)00108-6).
- [10] Selvan SR, Ganapathy D. Efficacy of fifth generation cephalosporins against methicillin-resistant *Staphylococcus aureus*-A review. *Research Journal of Pharmacy and Technology* 2016;9:1815. <https://doi.org/10.5958/0974-360x.2016.00369.3>.
- [11] Daou EE. The elastomers for complete denture impression: A review of the literature. *The Saudi Dental Journal* 2010;22:153–60. <https://doi.org/10.1016/j.sdentj.2010.07.005>.
- [12] Starcke EN. A historical review of complete denture impression materials. *The Journal of the American Dental Association* 1975;91:1037–41. <https://doi.org/10.14219/jada.archive.1975.0531>.
- [13] Ganapathy D, Sathyamoorthy A, Ranganathan H, Murthykumar K. Effect of Resin Bonded Luting Agents Influencing Marginal Discrepancy in All Ceramic Complete Veneer Crowns. *J ClinDiagn Res* 2016;10:ZC67–70.
- [14] Jain A, Ranganathan H, Ganapathy D. Cervical and incisal marginal discrepancy in ceramic laminate veneering materials: A SEM analysis. *Contemporary Clinical Dentistry* 2017;8:272.

- https://doi.org/10.4103/ccd.ccd_156_17.
- [15] Singla S. Complete denture impression techniques: Evidence-based or philosophical. *Indian Journal of Dental Research* 2007;18:124. <https://doi.org/10.4103/0970-9290.33788>.
- [16] Vijayalakshmi B, Ganapathy D. Medical management of cellulitis. *Research Journal of Pharmacy and Technology* 2016;9:2067. <https://doi.org/10.5958/0974-360x.2016.00422.4>.
- [17] Ashok V, Suvitha S. Awareness of all ceramic restoration in rural population. *Research Journal of Pharmacy and Technology* 2016;9:1691. <https://doi.org/10.5958/0974-360x.2016.00340.1>.
- [18] Ganapathy DM, Kannan A, Venugopalan S. Effect of Coated Surfaces influencing Screw Loosening in Implants: A Systematic Review and Meta-analysis. *World Journal of Dentistry* 2017;8:496–502. <https://doi.org/10.5005/jp-journals-10015-1493>.
- [19] Koodaryan R, Hafezeqoran A. Attitude of Dental practitioners Towards Complete Denture Impression Procedures. *Biomedical and Pharmacology Journal* 2016;9:345–8. <https://doi.org/10.13005/bpj/945>.
- [20] Ashok V, Nallaswamy D, Benazir Begum S, Nesappan T. Lip Bumper Prosthesis for an Acromegaly Patient: A Clinical Report. *J Indian Prosthodont Soc* 2014;14:279–82.
- [21] Bajunaid SO. A first experience with digital complete overdentures. *The Saudi Dental Journal* 2016;28:148–53. <https://doi.org/10.1016/j.sdentj.2015.12.006>.
- [22] Venugopalan S, Ariga P, Aggarwal P, Viswanath A. Magnetically retained silicone facial prosthesis. *Niger J ClinPract* 2014;17:260–4.
- [23] Complete denture fabrication methods. *Dental Abstracts* 2015;60:155. <https://doi.org/10.1016/j.denabs.2015.03.031>.
- [24] Kannan A, Venugopalan S. A systematic review on the effect of use of impregnated retraction cords on gingiva. *Research Journal of Pharmacy and Technology* 2018;11:2121. <https://doi.org/10.5958/0974-360x.2018.00393.1>.
- [25] Basha FYS, Ganapathy D, Venugopalan S. Oral Hygiene Status among Pregnant Women. *Research Journal of Pharmacy and Technology* 2018;11:3099. <https://doi.org/10.5958/0974-360x.2018.00569.3>.
- [26] Ajay R, Suma K, Ali S, Sivakumar JK, Rakshagan V, Devaki V, et al. Effect of surface modifications on the retention of cement-retained implant crowns under fatigue loads: An In vitro study. *Journal of Pharmacy And Bioallied Sciences* 2017;9:154. https://doi.org/10.4103/jpbs.jpbs_146_17.
- [27] El-Khodary NM, Shaaban NA, Abdel-Hakim AM. Effect of complete denture impression technique on the oral mucosa. *The Journal of Prosthetic Dentistry* 1985;53:543–9. [https://doi.org/10.1016/0022-3913\(85\)90644-4](https://doi.org/10.1016/0022-3913(85)90644-4).
- [28] Jamieson CH. A complete denture impression technique. *The Journal of Prosthetic Dentistry* 1954;4:17–29. [https://doi.org/10.1016/0022-3913\(54\)90061-x](https://doi.org/10.1016/0022-3913(54)90061-x).
- [29] Shannon JL. Essentials of complete denture prosthodontics. *The Journal of Prosthetic Dentistry* 1981;46:465. [https://doi.org/10.1016/0022-3913\(81\)90462-5](https://doi.org/10.1016/0022-3913(81)90462-5).
- [30] Zinner ID, Sherman H. An analysis of the development of complete denture impression techniques. *The Journal of Prosthetic Dentistry* 1981;46:242–9. [https://doi.org/10.1016/0022-3913\(81\)90208-0](https://doi.org/10.1016/0022-3913(81)90208-0).
- [31] Subasree S, Murthykumar K, Dhanraj. Effect of Aloe Vera in Oral Health-A Review. *J Adv Pharm Technol Res* 2016;9:609.