

Surgical Anatomy of Facial Nerve in Rabbits

¹ Wissam Abdullah Alhayani, ² Maher MA, ³ Omar Tariq Hammoodi

Abstract- *surgical and anatomical exploration to the extra-cranial distribution of facial nerve branches has a great surgical important to provide a clear model for nerve surgery. The present study was to illustrate of the anatomy of extra-cranial branches of facial nerve in rabbits. Eight adult New-Zealand rabbits (clinically healthy weighing from 2.5 to 3 kg, 4 males and 4 females) had been studied in this investigation. The rabbits divided into two equal groups. In group (A) the rabbits were injected fresh after euthanasia, through common carotid artery and through jugular vein, by colored latex to investigate and reveal the course of the facial nerve in relation to facial blood vessels, while in group (B), the rabbits were injected by 10% formalin through common carotid artery and left for 2-3 days soaked with formalin and then dissected to follow up the branches of facial nerve. The results showed that, the facial nerve in rabbits is a good model for experimental surgery for nerve and anatomical little variance in its branches with man and other species.*

Keywords- *Anatomy, Facial Nerve, Surgery, model and Rabbits*

Introduction

The facial nerve is the seven cranial nerve which arise from the *nervus facialis* nuclei at medulla oblongata (1). Facial nerve is divided into intra cranial and extra cranial courses (2). The facial nerve has motor and sensory divaricate branch provide sensation to the area around ear (outer ear) and rostral two-thirds of tongue (taste) and motor innervation muscle facial expressions, caudal part of digastricus, lacrimal glands, mandibular and sublingual salivary glands (3,4). Impairment resulting from injury to the facial nerve is associated with complex anatomy to help determine the level of injury, predict recovery, and guide surgical management (5). Rabbits are valuable model for many surgical experiment (6,7,8). The anatomy of the facial nerve is among the most complex of the cranial nerves. Anatomical description of the facial nerves and its correlations in small laboratory animals as rabbits is of great importance in small laboratory animals as rabbits and very useful for an adequate surgical application, so the present study was for explanation of the anatomy of extra cranial branches of rabbit facial nerve.

Materials and Methods

¹ Department of Veterinary Surgery and Obstetrics, College of Veterinary Medicine, University of Fallujah. Iraq.
E-mail: wisamabd82@uofallujah.edu.iq

² Department of Anatomy and Embryology, Faculty of Veterinary Medicine, Cairo University, Giza, Egypt

³ Department of Veterinary Surgery and Obstetrics, College of Veterinary Medicine, University of Fallujah. Iraq.

Eight adult New-Zealand rabbits (clinically healthy weighing from 2.5 to 3 kg, 4 males and 4 females) had been used in this study. The rabbits divided into two equal groups, each group containing four animals. Rabbits were euthanized by exsanguination after anesthesia (9).

For anatomical investigation of the extra cranial branches of the facial nerve of rabbits, the animals in group (A) were injected fresh after euthanasia, through common carotid artery and through jugular vein, by colored latex to investigate and reveal the course of the facial nerve in relation to facial blood vessels, while in group (B), the rabbits were injected by 10% formalin through common carotid artery and left for 2-3 days soaked with formalin and then dissected to follow up the branches of facial nerve.

The anatomical nomenclatures used in the present study were adopted to the terminology of *Barone, 2001* (10) as well as to the recent available literatures.

Results and Discussion

By dissecting the skin at the face region, we observed the emergence of the facial nerve trunk (fig.1/1) from the stylomastoid foramen in the retromandibular region or parotid region under the cover of parotid salivary gland and base of ear (fig.2/15), here called the extra cranial part or parotideal part of the facial nerve.

Our investigations were similar to that reported by other authors (10,11,12), the result showed the rabbits facial nerve emerge from the stylomastoid foramen under parotid gland and then pierce the parotid gland and it continues to run over head to give other branches, during its course inside parotid gland the nerve diverge into about eight branches, six of these branches supply nerves to the superficial head and neck muscles. These are the auriculopalpebral (fig.1, 2/5), the internal auricular (fig.1, 2/6), the caudal auricular (fig.1,2/7), the cervical branch (ramus coli) (fig.1/9-2/8), digastric (fig.1/8), small parotideal, the marginal mandibular (fig.1, 2/4) then continues cranially on masseter muscle to give the buccal branches (fig.1, 2/2,3).

The current study revealed that there was a communication between the trigeminal nerve (fig.1/12-2/11) and the facial nerve in rabbits and the peripheral communications between the two nerves might provide one path by which sensory fibers could travel centrally from the muscles (15). On the other hand, the communications between the two previously mentioned nerves existed, there was no intermingling of their fibers (11).

Our results revealed that the facial nerve of rabbit gives the marginal mandibular branch at the caudal rim of the masseter muscle just cranial to the maxillary vein (fig.1/15) and descending cranioventrally on a straight line to reach the ventral border of mandible and masseter where it crossing over the facial vessels (fig.1/19). A result which was different from that found by *Sasaki et al., 2010* (12) that found, the marginal divaricating of mandibular branch of facial nerve in pig pass along the ventral edge of the ramus of mandible between the submandibular glands and medial pterygoid muscles, and side by side facial vessels on the medial border of the masseter muscle.

Our observations were in agreement with that investigated by *Bowden and Mahran, 1960* (11) in rabbits that many intact bundles of the infraorbital nerve (fig.1/11-2/10) remained separated from the upper buccal branch of the facial nerve (fig.1/2) and supplied overlying skin, mucous membrane but there was an intermingling of a proportion of fibers with the facial nerve which contained contributions from the trigeminal mandibular nerve. He also added that these communications were limited to the upper buccal division of the facial nerve.

Our overall macroscopic anatomy observations were agreed with *Costa et al., 2006 (13)* that observed that the anatomical aspect of the rabbit facial nerve was near to those of the man and animals' facial nerve with little anatomical discrepancy in its branches.

On conclusion, the facial nerve in rabbits is the best model for experimental surgery of nerve and little anatomical variance in its branches with man and other species.

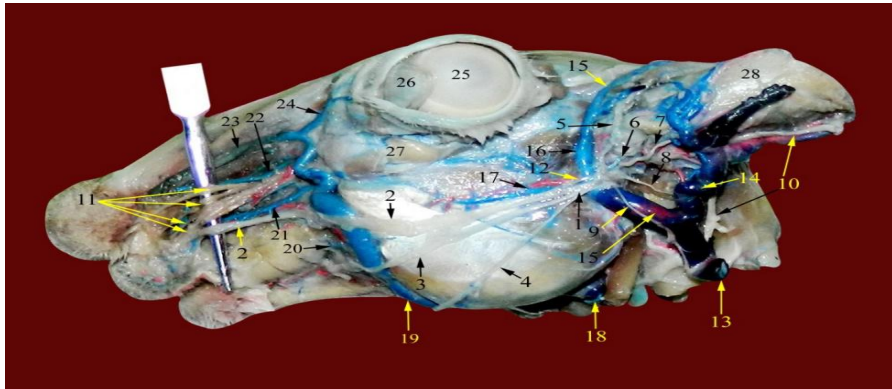


Figure (1): Extra-cranial branches of facial nerve in rabbit in relation to surrounding structures in group A:

1, Facial n. 2, Dorsal buccal branch. 3, Ventral buccal branch. 4, Marginal mandibular branch. 5, Auriculopalpebral n. 6, Internal auricular n. 7, Caudal auricular n. 8, Digastric n. 9, Ramus coli n. 10, Great auricular n. 11, Infra-orbital n. 12, Communicating branch of auriculotemporalis n. 13, Maxillary v. 14, Caudal auricular v. 15, Superficial temporal v. 16, Rostral auricular v. 17, Transverse facial v. 18, Lingofacial v. 19, Facial v. 20, Mandibular labial v. 21, Maxillary labial v. 22, Lateral nasal v. 23, Dorsal nasal v. 24, Angular v. of eye. 25, Cornea of eye. 26, Third eyelid. 27, Maxillary gland. 28, Auricle of ear (upper half cutted).

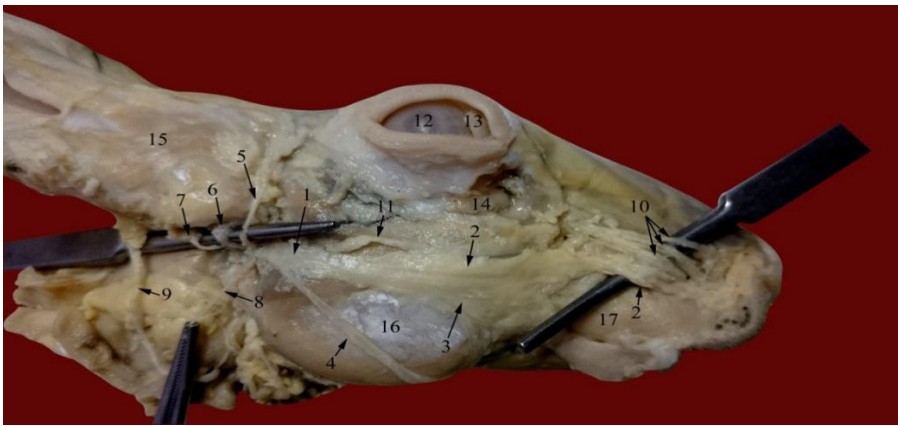


Figure (2): Extra-cranial branches of facial nerve in rabbit in relation to surrounding structures in group B:

1, Facial n. 2, Dorsal buccal branch. 3, Ventral buccal branch. 4, Marginal mandibular branch. 5, Auriculo-palpebral n. 6, Internal auricular n. 7, Caudal auricular n. 8, Ramus coli n. 9, Great auricular n. 10, Infra-orbital n. 11, Communicating branch of auriculotemporalis n. 12, Cornea of eye. 13, Third eyelid. 14, Maxillary gland. 15, Auricle of ear (upper half cutted). 16, masseter muscle. 17, Buccinator muscle.

REFERENCES

1. Sharp, N.J. (1985). Nervous system. In Slatter, D. H. Textbook of small animal surgery. W. B. Saunders Company USA. pp.1100.
2. Levine, S.M. and Esrig, R.P. (2000). The facial nerve in animals. In May, M. and Schaitkin, B.M. The facial nerve. 2nd Edition. Thieme Medical Publishers. New York. pp: 107-112.
3. Reece, W.O. (2005). Functional anatomy and physiology of domestic animals. 3rd ed. Lippincott Williams & Wilkins, Baltimore. USA. pp. 94.
4. Lorenz, M.D., Coates, J.R. and Kent, M. (2011). Handbook of Veterinary Neurology. Elsevier Saunders, USA. 5th Edition. pp: 283.
5. Myckatyn, T.M. and Mackinnon, S.E. (2004) A review of facial nerve anatomy. *Semin. Plast. Surg.* 18(1):5-12.
6. Alheani, W.A. and Al-Kennany, E.R. (2013). Partial Hepatectomy Achievement by New Device in Rabbits Model. *AL-Qadisiya Journal of Vet.Med.Sci.* 12 (1).1-14
7. Nazht, H.H. (2013). Histopathological study of the effect of the laser on the osteoblast cells during mandible defect in Rabbits. *Al-Anbar Journal of Veterinary Sciences* 6 (2), 31-36.
8. Ibrahim, R.S. (2017). Comparative study of some Histomorphological observations between the tongue of the wild rabbit breed (*Lepus capensis*) and local rabbit breed (*Oryctolagus cuniculus*). *Al-Anbar Journal of Veterinary Sciences* 10 (1), 15-19.
9. Olfert, E.D., Cross, B.M. and McWilliam, A.A. (1993). Guide to the care and use of experimental animals. The Canadian Council on Animal Care. 2nd Edition. pp:228.
10. Barone, R., (2001). Anatomie compare'e des mammife' res domestiques. *Splanchnologie II. Appareil uro-ge' nital, foetus et ses annexes, pe'ritoine et topographie abdominale*, vol. 4, 3rd edn. Paris: Vigot Fre' res, pp. 896.
11. Bowden, REM and Mahran, ZY (1960). Experimental and histological studies of the extrapetrous portion of the facial nerve and its communications with the trigeminal nerve in the rabbit. *Journal of Anatomy*, Vol. 94, Part 3.
12. Sasaki, R, Watanabe, Y, Yamato, M, Aoki, S, Okano, T and Ando, T (2010). Surgical anatomy of the swine face. *Laboratory Animals* 2010; 44: 359–363.
13. Costa, HJZR, da Silva, CF, Korn, GP and Lazarini, PR (2006). Posttraumatic facial nerve regeneration in rabbits. *Rev Bras Otorrinolaringol*; 72(6):786-93.