

# PREVALENCE OF STOMATITIS IN ANAEMIC PATIENTS- AN INSTITUTION BASED RETROSPECTIVE STUDY

Nivesh Krishna R<sup>1</sup>, Jayanth Kumar Vadive<sup>2</sup>, Arvind S<sup>3</sup>

## Abstract

*One of the most common oral manifestations of anaemia is anaemic stomatitis. Stomatitis refers to inflammation of the mouth and lips. In other words, it's an inflammatory process that affects the mucous membrane of the mouth and lips. The term stomatitis is derived from a greek word in which "stoma" refers to mouth and "itis" refers to inflammation. Anaemia is a global haematological disorder affecting people of almost all the age groups. It is estimated that almost one-third of the world's population is anaemic and are affected by one or other anaemic disorder. These disorders are mainly caused due to nutritional deficiencies that occur due to malnourishment or due to chronic intake of an imbalanced diet. The aim of this study was to determine the prevalence of stomatitis in patients with anemia. About 86000 records of the patients were obtained and screened for the presence of anaemia.. In this study, 47 patients who self-reported with anaemia were chosen. Among the 47 patients, 23 were male patients and 24 were female patients. This indicates that the predominant gender was female. To estimate the predominant age group affected by anaemia and anaemic stomatitis, the patients were divided into three groups. Group 1 includes 18-35 years, group 2 includes 36-50 years and group 3 includes 51-70 years of age. Both anaemia and anaemic stomatitis was predominantly seen among group 2 patients (36-50 years of age). 13 patients who were diagnosed with anaemic stomatitis, in the group of anemia patients. It was estimated that anaemic stomatitis was present in 27.7% of the study population. The association was performed with a chi-square test to associate between age, gender and anaemic stomatitis and a significant association was reported.*

**Keywords:** Anaemia, Burning sensation, Iron deficiency, Oral manifestations, Stomatitis

## I. Introduction

Anemia can be defined as a condition in which the total haemoglobin (Hb) level or number of red blood cells count(RBCs) in the blood is decreased. The World Health Organisation (WHO) defines anemia as Hb< 130g/L in men above 15 years, 110 g/L in pregnant women and <120g/L in non-pregnant women above 15 years of age[1]. The main etiology of anemia include, blood loss, decreased red cell production, and red cell destruction. Blood loss is the most common cause of anemia. The non-specific systemic signs and symptoms of anemia include mucous membrane pallor, tachypnea, raised jugular venous pressure, flow murmurs, postural hypotension, tachycardia, tiredness, lightheadedness, breathlessness, vertigo, development/ worsening of ischemic condition[2]. Along with these systemic manifestations, anemia may also manifest certain oral manifestations, some of which are specific and some are non-specific to the condition which include mucosal pallor, angular cheilitis, stomatitis, periodontal degeneration, dysphagia, depapillation of tongue[3].

---

<sup>1</sup> Saveetha Dental College and Hospitals, Saveetha Institute of Medical and Technical Sciences, Saveetha University, Chennai, India, Email: [151501014.sdc@saveetha.com](mailto:151501014.sdc@saveetha.com)

<sup>2</sup> Corresponding author : Reader, Department of Oral Medicine, Saveetha Dental College and Hospitals, Saveetha Institute of Medical and Technical Sciences, Saveetha University, Chennai - 600077, Email: [jayanthkumar@saveetha.com](mailto:jayanthkumar@saveetha.com)

<sup>3</sup> Reader, Department of Orthodontics, Saveetha Dental College and Hospitals, Saveetha Institute Of Medical and Technical Science, Saveetha University, Chennai, India, Email: [arvind.sdc@saveetha.com](mailto:arvind.sdc@saveetha.com)

The study of orofacial manifestations of these disorders is important because these orofacial signs and symptoms may be the first clinical presentation that alerts the dentist/hematologist to an underlying hematological disorder. The main cause for anaemia is due to various red cell defects and there are different types of anaemia. Aplastic anaemia is caused due to defect in production of RBC. Megaloblastic anaemia is caused due to defect in maturation of RBC. Iron deficiency anaemia is caused due to defects in haemoglobin synthesis and Thalassaemia is caused due to genetic defects that alter the haemoglobin maturation[4,5]. The oral manifestations of each type of anaemia can be discussed as follows. Iron deficiency anaemia includes angular cheilosis, atrophy and denudation of filiform papillae of tongue, increased risk of candidiasis and glossitis. Vitamin B12 (cyanocobalamin) deficiency includes angular cheilosis, stomatitis, oral paraesthesia, glossitis, oral pain, ulcerative gingivitis, denuded tongue, glossodynia wherein the tongue is "beefy" red, delayed wound healing, xerostomia[6]. Folic acid deficiency includes stomatitis, increased risk of candidiasis, glossitis, oral pain, ulceration, ulcerative gingivitis, glossitis, glossodynia, recurrent aphthous ulcers. Sickle cell anemia includes orofacial pain, paraesthesia of the mental nerve, pulpal necrosis, enamel hypomineralization, mandibular osteomyelitis, prominent maxilla with severe malocclusion, acute facial swelling, gingival enlargement and the oral manifestations of thalassaemia includes maxillary enlargement, bossing of the skull, malocclusion[7,8].

Iron deficiency anemia is characterized by incomplete synthesis of haemoglobin that results in microcytic and hypochromic red blood cells. Due to inadequate haemoglobin, there is reduction in the ability of blood to deliver oxygen to the other body cells and tissues. Glossitis, glossodynia, angular cheilitis, erythematous mucositis, oral candidiasis, recurrent oral ulcers and burning mouth are the common oral complaints and iron deficiency anemia should be suspected in any such case[9,10]. Previously our team has done many researches, systematic reviews and surveys which has led to the idea of the current topic on anaemic stomatitis[11-25]. The aim of the study was to estimate the prevalence of stomatitis in patients with anaemia.

## **II. MATERIALS AND METHODS:**

### **Sampling:**

The data and patient records were collected from June 2019 to March 2020. The case sheets of the patients between 18-70 years of age who had self reported to Saveetha Dental college with anaemia were reviewed. The data was verified using the DIAS software to prevent sampling bias. The external validity was good, as it is generalisable among patients of the same ethnic origins within the state and country.

### **Ethical approval:**

Ethical approval was obtained from the Institutional Ethical Committee and scientific review board [SRB] of Saveetha Dental College. SDC/SIHEC/2020/DIAS/DATA/0619-0320

### **Data collection:**

The data collected from June 2019 to March 2020 after screening 86000 records and study subjects were selected. Among the 86000 records, patients with anaemia were chosen and screened for anaemic stomatitis. The data collected included parameters such as the patient's name, age, gender and diagnosis. To estimate the predominant age group, patients were divided into 3 age groups and presence or absence of anaemic stomatitis were recorded separately. The sample size of the study was 47 patients. Patient data obtained was cross verified with the DIAS treatment photographs. The data was collected and tabulated in the excel sheet and imported to spss software for statistical analysis.

### **Statistical analysis:**

The data was imported to spss software by IBM version 25.0 for Windows OS in which the output variables were defined. The independent variables were age and gender whereas the dependent variables were the presence or absence of anaemic stomatitis and the statistical mean value obtained. The statistical test used was the chi-square test to establish the association between age, gender and number of patients with anaemic stomatitis and the test results were found to be significant at <0.05 level.

## Methodology

The data was imported to spss software by IBM version 25.0 for Windows OS in which the output variables were defined. The independent variables were age and gender whereas the dependent variables were the number of cases with anaemic stomatitis and the statistical mean value obtained for the prevalence. The study patients diagnosed with anaemic stomatitis were collected from DIAS records and chi square test was performed to obtain the results.

## III. RESULTS:

In this study, 47 patients who self-reported with anaemia were chosen and considered to be the case group. Among the 47 patients, 23 were male patients and 24 were female patients (figure 1). This indicates that the patients were nearly equally distributed in both genders.. To estimate the predominant age group affected by anaemia and anaemic stomatitis, the patients were divided into three groups. Group 1 includes 18-35 years with 2 patients, group 2 includes 36-50 years with 7 patients and group 3 includes 51-70 years of age with 4 patients affected by anaemic stomatitis respectively. From figure 2 it can be inferred that, both anaemia and anaemic stomatitis was predominantly seen among group 2 patients (36-50 years of age). It was estimated that anaemic stomatitis was present in 27.7% of the study population (figure 3). Table 1 and graph 4 shows the association between gender and anaemic stomatitis, table 2 and graph 5 shows the association between age group and anaemic stomatitis. The statistical test used was the chi-square test to establish the association between age, gender and number of patients with anaemic stomatitis and the test results were found to be significant at <0.05 level.

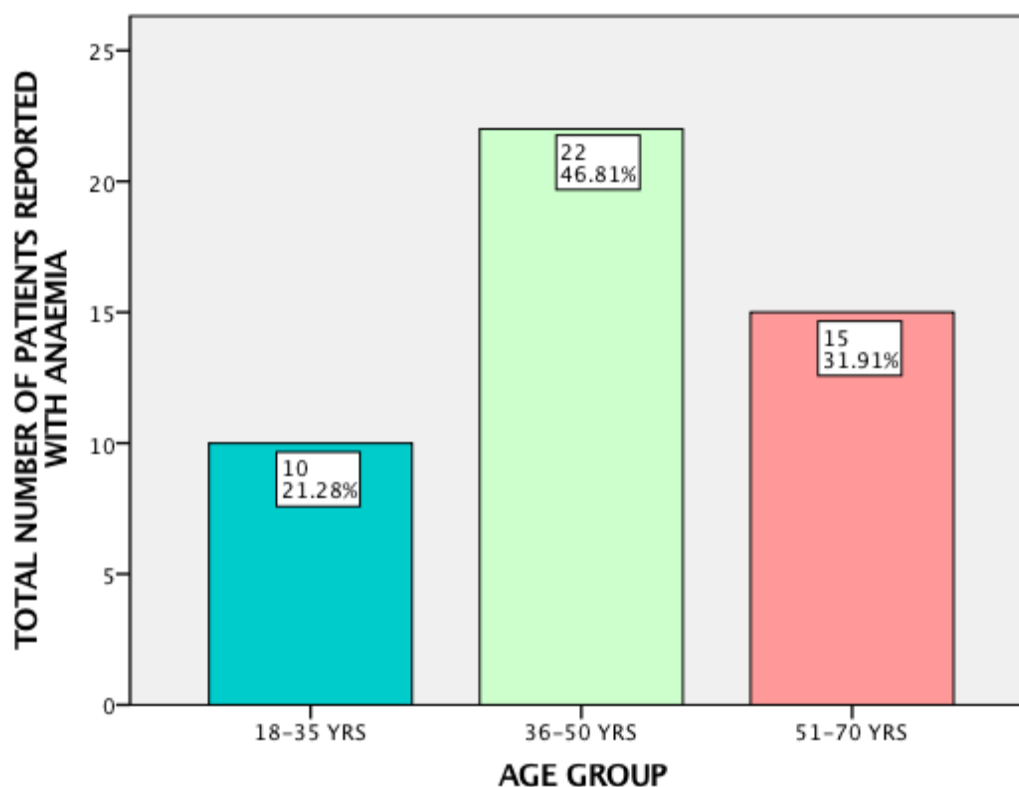


Figure 1 Bar graph showing the distribution of the patients across the three age groups. X axis represents the age group and Y axis represents the number of patients. A vast majority of the patients were seen in the 36-50 years of age group.

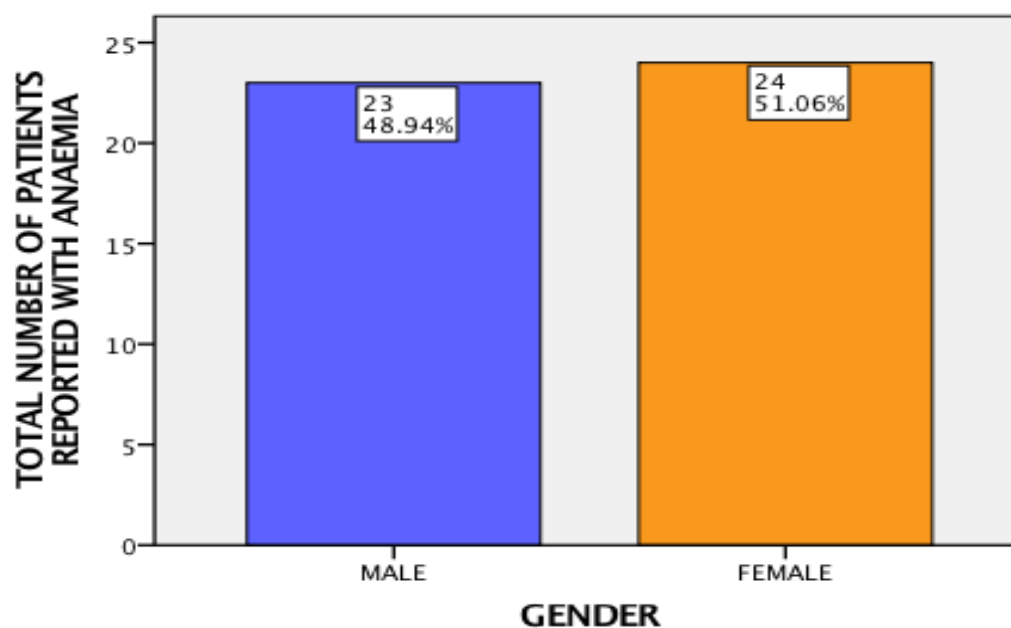


Figure 2 Bar graph showing the distribution of the patients across gender. X axis represents the gender and Y axis represents the number of patients. The number of females with anaemic stomatitis were slightly higher than males.

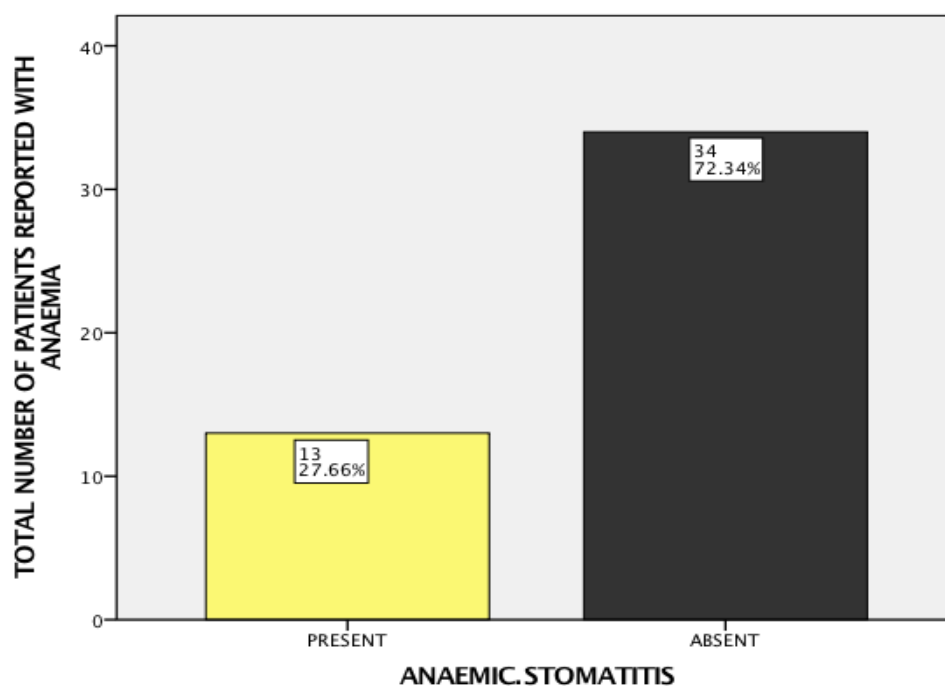


Figure 3 Bar graph showing the distribution of the patients across the presence or absence of anaemic stomatitis. X axis represents the anaemic stomatitis and Y axis represents the number of patients. Anaemic stomatitis seemed to be absent in a vast majority of the patients.

	ANAEMIC	STOMATITIS	
GENDER	PRESENT	ABSENT	TOTAL
MALE	5	18	23
FEMALE	8	16	24
TOTAL	13	34	47

Table 1: Table showing the gender based distribution of patients with anemic stomatitis

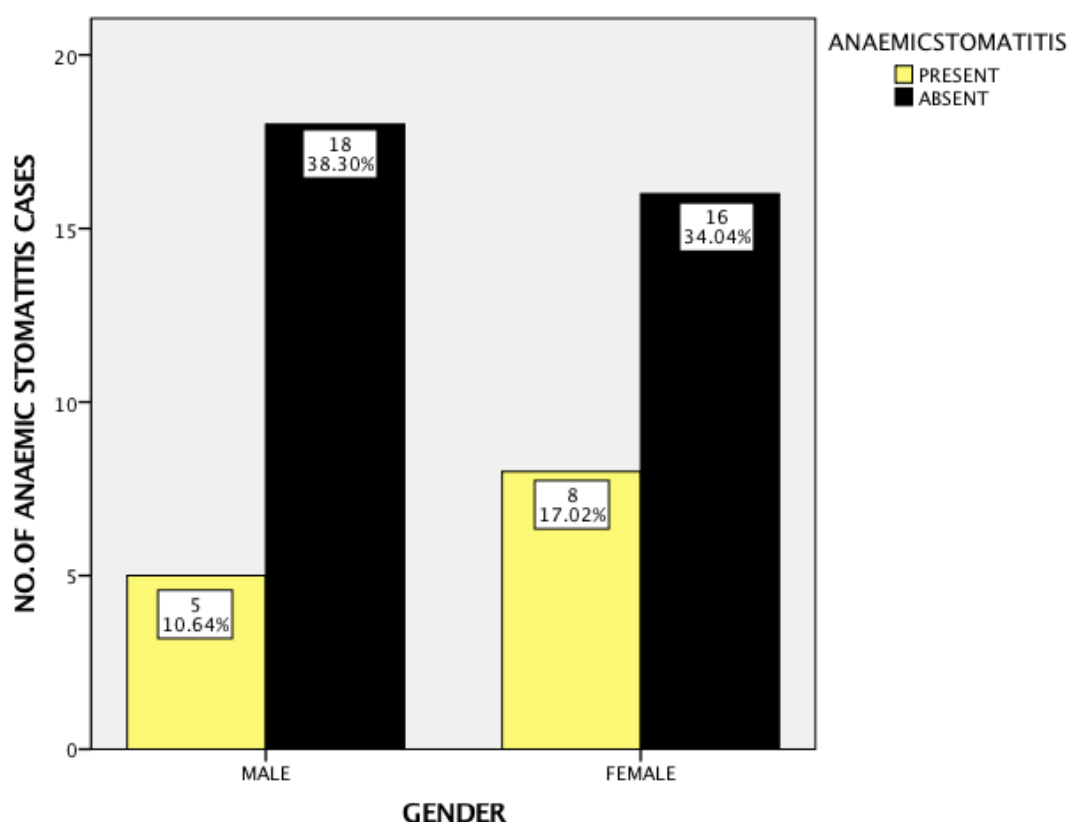


Figure 4: Bar graph showing the association between anemic stomatitis and the gender. X axis represents the gender and Y axis represents the number of patients. Prevalence of anaemic stomatitis was slightly higher in females than males. A chi-square association test (chi-square - 4.809;df-1;p-0.02(p<0.05)) gives a statistically significant association between gender and the presence of anemic stomatitis. Hence it can be inferred that there is a significant association between gender of the patient and the occurrence of anemic stomatitis.

	ANAEMIC	STOMATITIS	
AGE GROUP	PRESENT	ABSENT	TOTAL

18-35 YRS	2	8	10
36-50 YRS	7	15	22
51-70 YRS	4	11	15
TOTAL	13	34	47

Table 2: Table showing the age based distribution of patients with anemic stomatitis

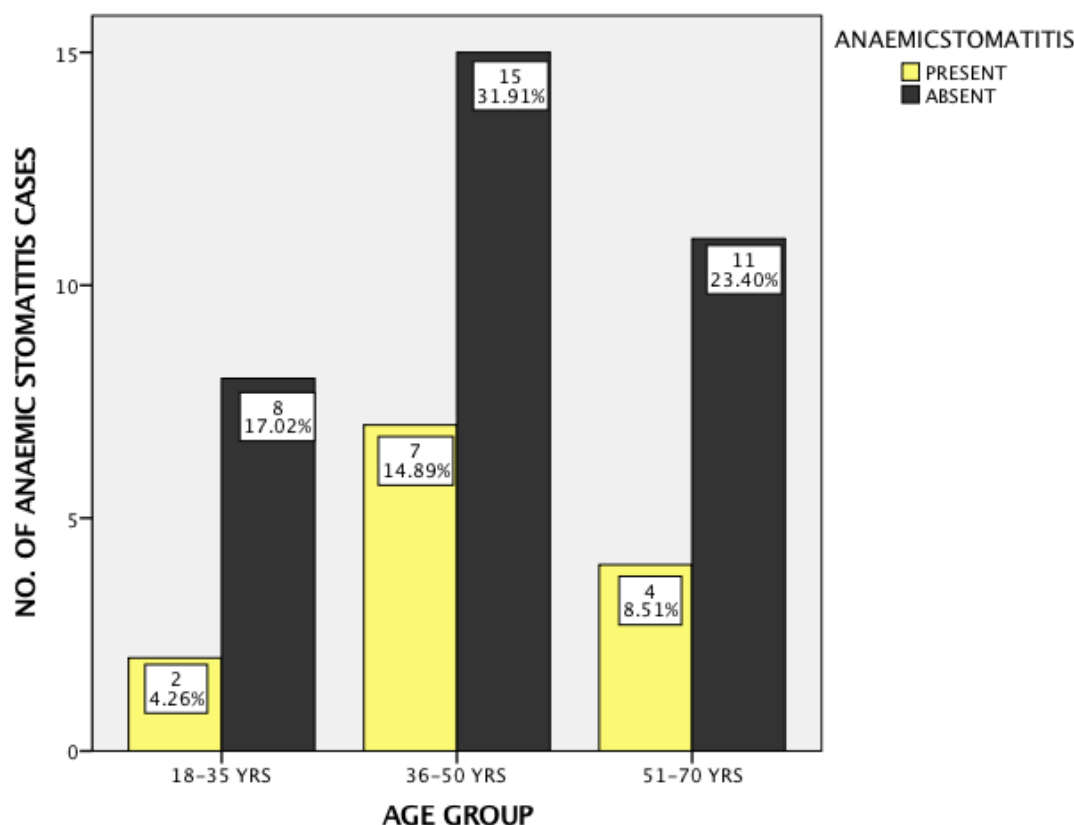


Figure 5: Bar graph showing the association between anemic stomatitis and the age groups. X axis represents the age groups and Y axis represents the number of patients. Group 2 (36-50 years) had a higher prevalence of anemic stomatitis than group 1 and 3. A chi-square association test (chi-square - 2.490;df-1;p-0.03(p<0.05)) gives a statistically significant association between age group and the presence of anemic stomatitis. Hence it can be inferred that there is a significant association of age and occurrence of anemic stomatitis.

#### IV. DISCUSSION:

Anaemic stomatitis presents itself as an inflammatory lesion affecting predominantly the buccal mucosa and less frequently, the tongue and palate in anaemic patients. Anaemic stomatitis, in general, occurs due to the deficiency of iron, folic acid and cobalamin. Majority of the studies state that it affects upto 25% of the general population and recurrence rate every 3rd month is as high as 50% [26]. In this case control study, there were 23 male patients and 24 female patients suggesting a female predominance. This coincides with the study done by Lopez A et al wherein 60% of anaemic patients were females when compared to the male patient

population[27]. In this study, all the patients who were diagnosed with anaemic stomatitis, had iron deficiency anaemia but other authors also suggested that stomatitis is a common symptom in other types of anaemia such as aplastic anaemia, pernicious anaemia and sickle cell anaemia. A study by Hjorting Hansen E et al discussed the oral aspects of pernicious anaemia indicating stomatitis to be the main oral manifestation[28]. In this study, through the statistical chi-square test, it was determined that anaemic stomatitis was present in 27.7% of the study population. Studies on the same area of interest have indicated that the inflammatory lesions like ulcers attain a red colour, thereby leading to a burning and itching sensation culminating in masticatory difficulties.. These lesions may also mimic recurrent aphthous stomatitis by their appearance[29,30].

Some authors also discussed the taste alteration caused by the stomatitis lesions in anaemic patients[31]. Comparing with the other similar studies, a study by Van Dis ML et al indicates 68% of the study population had anaemic stomatitis, which is in contradiction to our study[32]. A study by Long RG et al indicated that glossitis and stomatitis are present in almost 70% of the patients diagnosed with anaemia, this study is also in contradiction to our study[33]. Another study by McFarlane DB et al indicated that iron deficiency anaemia is the most common type of anaemia and anaemic stomatitis to be the most predominant oral manifestation, commonly seen in female patients[34]. This is in correlation with our study. From the study, it is understood that anaemic stomatitis is an inflammatory ulcerative condition of the oral mucosa characterized by ulcers, that are commonly seen in iron deficiency anaemia.

The pathogenesis of anaemic stomatitis can be explained as follows: Anaemia is mainly caused by the deficiency of iron. Iron is systematically produced from the bone marrow through the type of cells called red blood cells or erythrocytes. Iron in the diet is of two types, haem iron and non heme iron[35]. Iron is required for the regulation of transcriptional elements necessary for cell replication and cell repair. In case of iron deficiency, this process gets deteriorated leading to lack of cell replication and cell repair. This elicits severe inflammatory changes which mainly occurs in buccal mucosa of the oral cavity. These are predominantly ulcerative and sometimes non ulcerative causing stomatitis[36,37]. Since The management of these types of lesions, thus, involves management of the underlying systemic condition. In our study, the reason for lower prevalence is mainly due to the screening of patients who were self reported with anaemia for the presence or absence of anaemic stomatitis.

#### **Limitations:**

This case control study is limited to the patients who were self reported with anaemia confined to a particular geographical area. This study does not include any other entity apart from anaemic stomatitis.

#### **Future scope:**

This study gives a vast idea on anaemia, its classification, prevention and management of anaemic disorders affecting the oral cavity; in an effective way.

## **V. CONCLUSION:**

Within the limitations of the study, it can be concluded that stomatitis was seen in 27.7% (13 )patients with anaemia. A significant association of age and gender with prevalence of anaemic stomatitis was noted. Prevalence of stomatitis due to anemia was more in females and patients in the age range of 36-50 years. Performing oral screening to diagnose the oral manifestations of systemic disorders at the earliest can be done to take necessary steps in order to treat the condition.

#### **Author Contributions:**

First author [Nivesh Krishna R] performed analysis, interpretation and wrote the manuscript. Second author [Dr. Jayanth Kumar] contributed to conception, data designs, analysis, interpretation and critically revised the manuscript. Third author [Dr. Arvind Sivakumar] participated in the study and revised the manuscript. All the three authors have discussed the results and contributed to the final manuscript.

#### **Acknowledgement:**

I sincerely express my gratitude and acknowledgement to Dr.Jayanth Kumar and Dr.Arvind Sivakumar and Dean and management for their support and also thank the Research and IT department of Saveetha dental college (SIMATS) for their affable assistance in analyzing the data.

**Conflict Of Interest:** Nil.

## REFERENCES:

- [1] Marchini, L., M. S. Campos, A. M. Silva, L. C. Paulino, and F. G. Nobrega. 2007. "Bacterial Diversity in Aphthous Ulcers." *Oral Microbiology and Immunology*. <https://doi.org/10.1111/j.1399-302x.2006.00345.x>.
- [2] Thornhill, M. H., L. Baccaglini, M. Bazrafshani, and W. Ollier. 2004. "Association between Gene Polymorphisms and Pain Severity in Patients with Recurrent Aphthous Stomatitis (RAS)." *Oral Surgery, Oral Medicine, Oral Pathology, Oral Radiology, and Endodontology*. <https://doi.org/10.1016/j.tripleo.2004.02.029>.
- [3] Ezzati M, Lopez AD, Rodgers A, Hoorn SV, Murray CJL. Selected major risk factors and global and regional burden of disease. *The Lancet* 2002;360:1347–60. [https://doi.org/10.1016/s0140-6736\(02\)11403-6](https://doi.org/10.1016/s0140-6736(02)11403-6).
- [4] Carrozzo, M., D. Conrotto, M. Carbone, and S. Gandolfo. 2006. "No Evidence for Therapeutic Effect of Topical Ciclosporin in Oral Lichen Planus: Reply from Authors." *British Journal of Dermatology*. <https://doi.org/10.1111/j.1365-2133.2006.07335.x>.
- [5] DiMarco, Connie S. 2000. "Speroff L, Glass RH, Kase NG, Editors. Clinical Gynecologic Endocrinology and Infertility. 6th Ed. Baltimore: Lippincott, Williams & Wilkins, 1999:1–1200." *Fertility and Sterility*. [https://doi.org/10.1016/s0015-0282\(00\)00647-6](https://doi.org/10.1016/s0015-0282(00)00647-6).
- [6] Erturk, Emine Yurdakul, Abdullah Dağlı, and Abdullah Erdil. 2017. "Periodic Fever, Aphthous Stomatitis, Pharyngitis and Cervical Adenitis Syndrome: Report of Four Cases." *Tuberculin Skin Test in Children*. <https://doi.org/10.5222/j.child.2017.131>.
- [7] Field, E. A., and R. B. Allan. 2003. "Oral Ulceration - Aetiopathogenesis, Clinical Diagnosis and Management in the Gastrointestinal Clinic." *Alimentary Pharmacology and Therapeutics*. <https://doi.org/10.1046/j.1365-2036.2003.01782.x>.
- [8] Jacobs, A. 1961. "Carbohydrates and Sulphur-Containing Compounds in the Anaemic Buccal Epithelium." *Journal of Clinical Pathology* 14 (November): 610–14.
- [9] Porter, S. R., V. Kingsmill, and C. Scully. 1993. "Audit of Diagnosis and Investigations in Patients with Recurrent Aphthous Stomatitis." *Oral Surgery, Oral Medicine, Oral Pathology*. [https://doi.org/10.1016/0030-4220\(93\)90011-r](https://doi.org/10.1016/0030-4220(93)90011-r).
- [10] Porter, S. R., C. Scully, and S. Flint. 1988. "Hematologic Status in Recurrent Aphthous Stomatitis Compared with Other Oral Disease." *Oral Surgery, Oral Medicine, Oral Pathology*. [https://doi.org/10.1016/0030-4220\(88\)90064-3](https://doi.org/10.1016/0030-4220(88)90064-3).
- [11] Venugopal A, Maheswari TNU. Expression of matrix metalloproteinase-9 in oral potentially malignant disorders: A systematic review. *Journal of Oral and Maxillofacial Pathology* 2016;20:474. <https://doi.org/10.4103/0973-029x.190951>.
- [12] Chaitanya NC, Muthukrishnan A, Babu DBG, Kumari CS, Lakshmi MA, Palat G, et al. Role of Vitamin E and Vitamin A in Oral Mucositis Induced by Cancer Chemo/Radiotherapy- A Meta-analysis. *J Clin Diagn Res* 2017;11:ZE06–9.
- [13] Subashri A, Uma Maheshwari TN. Knowledge and attitude of oral hygiene practice among dental students. *Research Journal of Pharmacy and Technology* 2016;9:1840. <https://doi.org/10.5958/0974->

360x.2016.00375.9.

- [14] Maheswari TNU, Venugopal A, Sureshababu NM, Ramani P. Salivary micro RNA as a potential biomarker in oral potentially malignant disorders: A systematic review. *Ci Ji Yi Xue Za Zhi* 2018;30:55–60.
- [15] Misra SR, Shankar YU, Rastogi V, Maragathavalli G. Metastatic hepatocellular carcinoma in the maxilla and mandible, an extremely rare presentation. *Contemp Clin Dent* 2015;6:S117–21.
- [16] Lambris JD, Michael Holers V, Ricklin D. Complement Therapeutics. Springer Science & Business Media; 2012.
- [17] Warnakulasuriya S, Muthukrishnan A. Oral health consequences of smokeless tobacco use. *Indian Journal of Medical Research* 2018;148:35. [https://doi.org/10.4103/ijmr.ijmr\\_1793\\_17](https://doi.org/10.4103/ijmr.ijmr_1793_17).
- [18] Patil SR, Maragathavalli G, Araki K, Al-Zoubi IA, Sghaireen MG, Gundapaneni RK, et al. Three-Rooted Mandibular First Molars in a Saudi Arabian Population: A CBCT Study. *Pesqui Bras Odontopediatria Clin Integr* 2018;18:4133.
- [19] Subha M, Arvind M. Role of Magnetic Resonance Imaging in Evaluation of Trigeminal Neuralgia with its Anatomical Correlation. *Biomedical and Pharmacology Journal* 2019;12:289–96. <https://doi.org/10.13005/bpj/1640>.
- [20] Muthukrishnan A, Bijai Kumar L. Actinic cheilosis: early intervention prevents malignant transformation. *BMJ Case Rep* 2017;2017. <https://doi.org/10.1136/bcr-2016-218654>.
- [21] Choudhury P. Vanishing Roots: First Case Report of Idiopathic Multiple Cervico–Apical External Root Resorption. *JOURNAL OF CLINICAL AND DIAGNOSTIC RESEARCH* 2015. <https://doi.org/10.7860/jcdr/2015/11698.5668>.
- [22] Chaitanya NC, Muthukrishnan A, Krishnaprasad CMS, Sanju Prasanna G, Pillay P, Mounika B. An Insight and Update on the Analgesic Properties of Vitamin C. *J Pharm Bioallied Sci* 2018;10:119–25.
- [23] Muthukrishnan A, Bijai Kumar L, Ramalingam G. Medication-related osteonecrosis of the jaw: a dentist's nightmare. *BMJ Case Rep* 2016;2016. <https://doi.org/10.1136/bcr-2016-214626>.
- [24] Rohini S, Kumar VJ. Incidence of dental caries and pericoronitis associated with impacted mandibular third molar-A radiographic study. *Research Journal of Pharmacy and Technology* 2017;10:1081–4.
- [25] Dharman S, Muthukrishnan A. Oral mucous membrane pemphigoid - Two case reports with varied clinical presentation. *J Indian Soc Periodontol* 2016;20:630–4.
- [26] Lahner E, Annibale B. Pernicious anemia: new insights from a gastroenterological point of view. *World J Gastroenterol* 2009;15:5121–8.
- [27] Lopez A, Cacoub P, Macdougall IC, Peyrin-Biroulet L. Iron deficiency anaemia. *Lancet* 2016;387:907–16.
- [28] Hjorting-Hansen E, Bertram U. Oral aspects of pernicious anaemia. *Br Dent J* 1968;125:266–70.
- [29] Gupta S, Swarup N, Sairam H, Sinha N, Nair SS. Orofacial Manifestations associated with Anemia. *World Journal of Anemia* 2017;1:44–7. <https://doi.org/10.5005/jp-journals-10065-0010>.
- [30] Adeyemo TA, Adeyemo WL, Adediran A, Akinbami AJA, Akanmu AS. Orofacial manifestations of hematological disorders: anemia and hemostatic disorders. *Indian J Dent Res* 2011;22:454–61.
- [31] Barron RW. Treatment strategies for recurrent oral aphthous ulcers. *American Journal of Health-System Pharmacy* 2001;58:41–50. <https://doi.org/10.1093/ajhp/58.1.41>.

- [32] Van Dis ML, Langlais RP. The thalassemias: oral manifestations and complications. *Oral Surg Oral Med Oral Pathol* 1986;62:229–33.
- [33] Long RG, Hlousek L, Doyle JL. Oral manifestations of systemic diseases. *Mt Sinai J Med* 1998;65:309–15.
- [34] McFarlane DB, Pinkerton PH, Dagg JH, Goldberg A. Incidence of iron deficiency, with and without anaemia, in women in general practice. *Br J Haematol* 1967;13:790–6.
- [35] Sun A, Chen H-M, Cheng S-J, Wang Y-P, Chang JY-F, Wu Y-C, et al. Significant association of deficiencies of hemoglobin, iron, vitamin B12, and folic acid and high homocysteine level with recurrent aphthous stomatitis. *Journal of Oral Pathology & Medicine* 2015;44:300–5. <https://doi.org/10.1111/jop.12241>.
- [36] Morris MS, Jacques PF, Rosenberg IH, Selhub J. Folate and vitamin B-12 status in relation to anemia, macrocytosis, and cognitive impairment in older Americans in the age of folic acid fortification. *Am J Clin Nutr* 2007;85:193–200.
- [37] Farhat Yaasmeen Sadique Basha, Rajeshkumar S, Lakshmi T, Anti-inflammatory activity of *Myristica fragrans* extract . *Int. J. Res. Pharm. Sci.*, 2019 ;10(4), 3118-3120 DOI: <https://doi.org/10.26452/ijrps.v10i4.1607>
- [38] Ship JA. Recurrent aphthous stomatitis. *Oral Surgery, Oral Medicine, Oral Pathology, Oral Radiology, and Endodontology* 1996;81:141–7. [https://doi.org/10.1016/s1079-2104\(96\)80403-3](https://doi.org/10.1016/s1079-2104(96)80403-3).